



ELSEVIER

Contents lists available at ScienceDirect

Comptes Rendus Palevol

www.sciencedirect.com



Human palaeontology and prehistory (Palaeopathology)

Palaeopathology of the Pleistocene specimen D2600 from Dmanisi (Republic of Georgia)



Paléopathologie du spécimen pléistocène D2600 de Dmanisi (république de Géorgie)

Laura Martín-Francés^{a,*}, María Martín-Torres^a, Elena Lacasa-Marquina^a, Pilar Fernández-Colón^a, Ana Gracia-Téllez^{c,d}, José María Bermúdez de Castro^a

^a National Research Centre on Human Evolution (CENIEH), Paseo de la Sierra de Atapuerca s/n, 09002 Burgos, Spain

^b Área de Antropología Física, Departamento de Ciencias de la Vida, Universidad de Alcalá de Henares, Edificio de Ciencias, Campus Universitario, 28871 Alcalá de Henares, Spain

^c Área de Paleontología, Departamento de Geología, Universidad de Alcalá de Henares, Edificio de Ciencias, Campus Universitario, 28871 Alcalá de Henares, Spain

^d Centro Mixto UCM-ISCIH de Investigación sobre Evolución y Comportamiento Humanos, Monforte de Lemos 5, Pabellón 14, 28029 Madrid, Spain

ARTICLE INFO

Article history:

Received 15 May 2013

Accepted after revision 16 October 2013

Available online 18 January 2014

Handled by Yves Coppens

Keywords:

Palaeopathology

Homo georgicus

Dmanisi site

Dental wear

Compensatory eruption

Periodontal disease

Cysts

ABSTRACT

Here we present a detailed palaeopathological study of the hominin mandible D2600 recovered at the Dmanisi site, Republic of Georgia. The Dmanisi assemblage represents the earliest evidence of hominins outside Africa with an age of 1.8 Ma. D2600 is the holotype of *Homo georgicus* species and its taxonomic assignment is still under debate. Our study reveals severe and unusual dental wear accompanied of extensive root exposure and dental axial migration, periapical abscesses and enamel fractures. In addition, there is evidence of post-eruptive tooth rotation and temporomandibular arthropathy. We propose that the wear pattern observed in this individual is related to a diet with a high intake of fibrous and abrasive foods such as fruits and plants, as it is usually recorded in chimpanzees and gorillas and unlike the wear pattern observed in other *Homo* specimens of our comparative sample. The rounded occlusal surfaces and highly polished labio-lingual surfaces of D2600 anterior teeth could be mainly the consequence of pre- and/or para-masticatory activities such as gripping and stripping. This type of food would be also the origin of the highly cupped occlusal morphology of the posterior dentition in combination with relatively slight approximal attrition. However, the lesions exhibited by D2600 have not significantly altered the morphology of the mandible and do not prevent a proper taxonomic assessment.

© 2013 Académie des sciences. Published by Elsevier Masson SAS. All rights reserved.

R É S U M É

Ici est présentée une étude paléopathologique détaillée de la mâchoire humaine D2600, recueillie au site de Dmanisi, en république de Géorgie. L'assemblage de Dmanisi représente la preuve la plus récente d'homininiens hors de l'Afrique; il est daté de 1,8 Ma. D2600 est l'holotype de l'espèce *Homo georgicus*, et son attribution taxonomique est encore débattue. Notre étude révèle une usure sévère et inhabituelle, avec exposition extensive de la racine et déplacement axial de la dent, abcès péri-apicaux et fractures de l'émail. En outre, il y a rotation de la dent après l'éruption dentaire et arthropathie temporo-maxillaire. Les auteurs

Mots clés :

Paléopathologie

Homo georgicus

Dmanisi (site de)

Usure dentaire

Éruption compensatoire

Maladie parodontale

Kystes

* Corresponding author.

E-mail address: lauramartinfrancesmf@gmail.com (L. Martín-Francés).

proposent de relier le patron d'usure observé chez cet individu à son alimentation, avec ingestion importante de nourriture fibreuse et abrasive, tels que fruits et plantes, comme on le rapporte couramment chez les chimpanzés et les gorilles, mais contrairement à ce qu'indique le patron d'usure observé chez d'autres spécimens d'*Homo* de notre échantillonnage de comparaison. Les surfaces occlusales arrondies et les surfaces labio-linguales fortement polies des dents antérieures de D2600 pourraient surtout être la conséquence d'activités pré- ou para-masticatrices de saisie et d'arrachage. Ce type de nourriture serait aussi à l'origine de la morphologie occlusale fortement évasée de la dentition postérieure, combinée à une attrition relativement légèrement approximale. Cependant, les lésions que présente D2600 n'ont pas significativement altéré la morphologie de la mâchoire et n'empêchent pas l'appréciation taxonomique propre.

© 2013 Académie des sciences. Publié par Elsevier Masson SAS. Tous droits réservés.

1. Introduction

The Dmanisi site is located in the South of the Republic of Georgia. The excavation has yielded a rich sample of lithics, hominins and faunal fossils dated to the Pleistocene period (1.81–1.77 Ma) (Gabunia et al., 2000, Gabunia et al., 2002). The hominin assemblage comprises cranial and post-cranial remains of at least five individuals (Lordkipanidze et al., 2007; Rightmire et al., 2006, 2008; Vekua et al., 2002). The Dmanisi remains have been attributed to *Homo erectus* (Gabunia and Vekua, 1995; Rightmire et al., 2006), late *H. erectus* (Bräuer and Schultz, 1996); *H. sp. indet.* (*aff. ergaster*; Rosas and Bermúdez de Castro, 1998), *H. ex gr. ergaster* (Gabunia et al., 2000). According to Gabunia et al. (2002), D2600 mandible presents distinctive morphological characteristics, compared to those of *Homo habilis* and *H. erectus*, leading to the naming of a new species, *Homo georgicus*, of which D2600 is the holotype. However, the taxonomic assignment of the complete fossil assemblage to only one species has raised controversy (e.g., Gabunia et al., 2002; Margvelashvili et al., 2013; Martínón-Torres et al., 2008; Rightmire et al., 2008; Skinner et al., 2006). Morphological and metrical differences between D2600 individual and the rest of Dmanisi mandibles have been attributed to a marked sexual dimorphism by some researchers (Gabunia et al., 2002; Rightmire et al., 2008). However, other scholars suggest that the metric and morphological analysis of the mandibular corpus and the teeth could evince the existence of two different species in the Dmanisi assemblage (Martínón-Torres et al., 2008; Skinner et al., 2006). Furthermore, in a recent study Margvelashvili et al. (2013) suggest that the dentognathic pathologies are key factors in causing the morphological variation within the Dmanisi hypodigm. Whether D2600 belongs to the same taxon as the rest of the hominins is still under revision (e.g., Martínón-Torres et al., 2008; Rightmire et al., 2008). The identification of several pathological processes in the D2600 mandible credits a more detailed palaeopathological study of the specimen in order to evaluate if the dentognathic lesions have significantly altered the morphology of the mandibles as stated by Margvelashvili et al. (2013). Additionally, this study could provide dietary, behavioural information about this early hominin population. We conducted an analysis of the alveolar bone morphology and height, root exposure, dental wear, enamel breakage and infectious processes.

2. Material

The study was carried out on the original fossil at the Georgian National Museum (Tbilisi). The D2600 specimen consists of a mandibular bone that presents fractures principally at the mandibular rami. The mandible preserves *in situ* all teeth except the right second premolar (RP4), left first molar (LM1) and second premolar (LP4) (Fig. 1).

2.1. State of preservation

The mandibular body is almost complete except for some fractures at the inferior border. Two fractures affect the right and left rami. The fractures of the rami are both oblique, follow an ascending direction and have caused the loss of the mandibular angle and the masseteric area. On the right side the fracture begins at the location of the M1 distal root and finishes 30 mm inferiorly to the condyle, and its total length is 90 mm. Moreover, the ramus exhibits crushing on the lateral side of the outer table and the breakage of the mandibular notch (Fig. 1d). On the left side the fracture has produced a greater bone loss than in the right side, and the total length of the area affected is of 85 mm. The breakage starts at the distal root of the M2 and finishes 35 mm inferiorly to the articular surface of the condyle; it also affects the mandibular notch and has produced the loss of the coronoid process (Fig. 1b). Finally, there is a minor third fracture that affects the left buccal aspect of the mandibular bone. The fracture at the LM2 and LM3 location, of approximately 30 mm, has caused the exposure of the M2 root – 17 mm – and the alveolar crest (AC) breakage at the M3 (Fig. 1).

The sharpness of the margins together with the lack of bone remodelling indicates that all three fractures are peri-postmortem and likely consequence of diagenetic processes.

Apart from these, the mandible presents a series of abnormalities of pathological origin; and therefore, they will be tackled in the following section.

3. Methods

The degree of wear (or *wear category*) was determined following the eight-score system proposed by Molnar (1971), based on the amount of dentine exposure. The plane

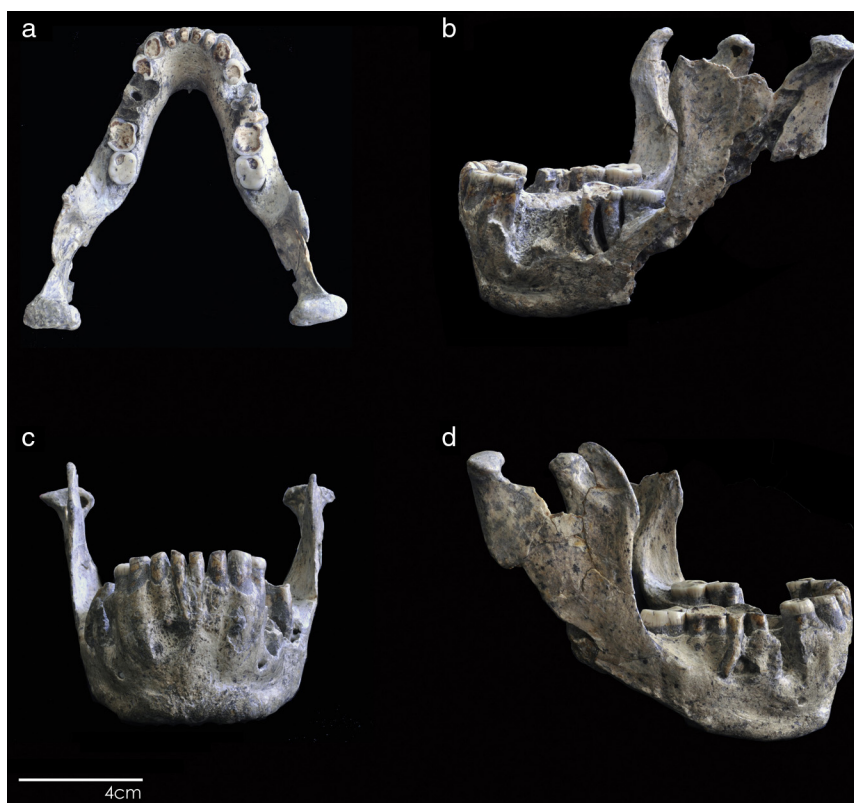


Fig. 1. D2600 mandible. a) Occlusal view; b) Left side; c) Anterior view; d) Right side. Scale bar 4 cm.

Fig. 1. Mâchoire D2600. a) Vue occlusale; b) Côté gauche; c) Vue antérieure; d) Côté droit. Barre d'échelle : 4 cm.

(or *direction of the wear*) was assessed from mesial and buccal views and following the eight-grade category of Molnar (1971). The occlusal morphology (*occlusal surface form*) was classified following Molnar (1971). The degree of dentine exposure on mesial and distal surfaces (*approximal attrition facets*) was scored according to the four-degree system developed by Hillson (2008).

We employed the definition and classification of Dias and Tyles (2007) for the assessment of periodontal cysts.

We measured the amount of root exposure, calculated as the distance between the AC and cemento–enamel junction (CEJ). It was wrongly assumed that the increased distance between the AC and the CEJ was exclusively reflecting the occurrence of periodontal disease. On the contrary, when the distance accompanies severe dental wear it can be a sign of *continuous eruption*, especially when there is lack of pathological signs (Clarke and Hirsch, 1991; Ogden, 2008a,b; Ten Cate, 1998). *Continuous eruption* is one of the three physiological tooth movements recognised to compensate for severe dental wear (e.g., Begg, 1954; d'Incau et al., 2012; Hylander, 1977; Kaifu et al., 2003).

The identification of periodontal disease in osteological collections is justified by the appearance of morphological changes in the alveolar bone crest (i.e., porosity, blunt–flat rim, ragged margin) and formation of a periodontal pocket of funnel shape (>5 mm) around the root. We applied Ogden (2008a) score system to assess the evidence (scores

2–4) or lack of signs (score 1) of periodontal disease in the alveolar bone.

Davies' definition of fenestration and dehiscence (Davies et al., 1974) was used to identify and classify the openings observed in the alveolar process. Dehiscence is characterised by “v” shape and the involvement of the alveolar margin. On the contrary, fenestration displays a quadrangular morphology and does not affect the alveolar margin (Clarke and Hirsch, 1991; Hillson, 2008; Nimigeau et al., 2009; Rupprecht et al., 2001).

We used Pattersons' (1984) classification to distinguish between two forms of enamel breakage: (a) minor chipping and (b) major segments of enamel loss or fracture.

To determine the moment of occurrence – pre-mortem vs. peri-mortem – it is important to analyse the morphology of the borders and the colouration of the fracture (Milner and Larsen, 1991; Scott and Winn, 2011; Smith, 1984); for this we followed Smiths' (1984) criteria.

Tooth rotation is defined as the tooth movement around its long axis (Harris and Corruccini, 2008; Natsume et al., 2006; Primožič et al., 2012). To assess the degree of tooth rotation (normal versus abnormal), we followed Natsume et al. (2006). The angle of rotation was calculated between: (a) the line perpendicular to the lingual surface of the tooth if this was in its correct position and (b) the line perpendicular to the current lingual surface of the tooth (see Fig. 2).

Finally, and for comparative purposes, we performed a paleopathological analysis of several original specimens,

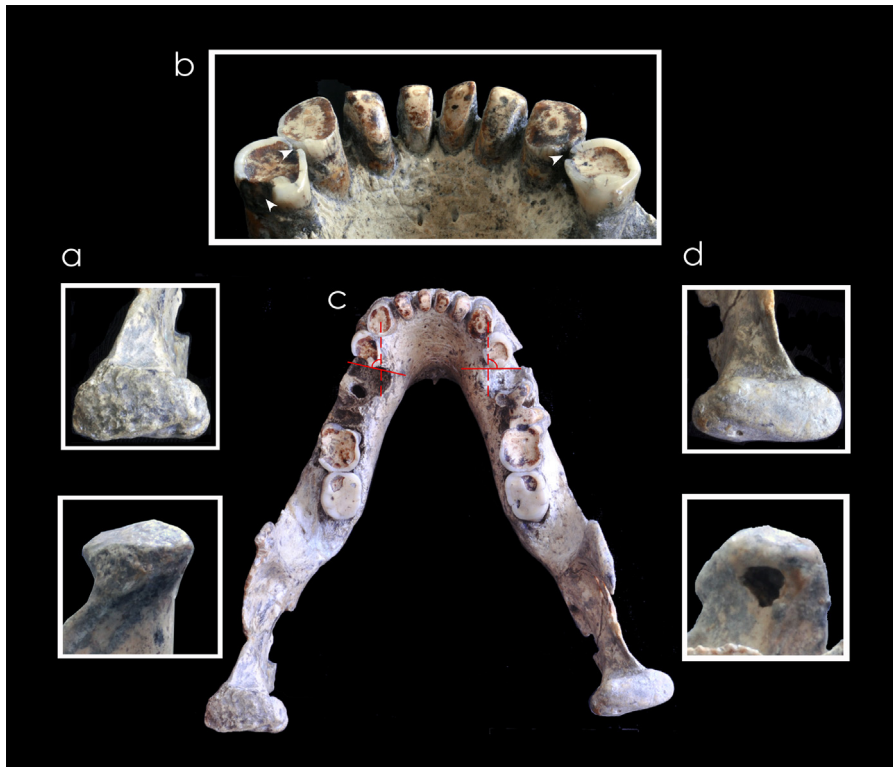


Fig. 2. D2600 mandible. a) Occlusal and medial view of left condyle; b) buccal view of incisors wear, approximal contact facets of RP3 and LP3 (white arrows) and enamel chipping; c) Occlusal view of RP3 and LP3 rotation; d) Occlusal and medial view of right condyle.

Fig. 2. Mâchoire D2600. a) Vue occlusale et médiale du condyle gauche ; b) Vue buccale de l'usure des incisives, facettes de contact approximales de RP3 et LP3 (flèches blanches) et éclats d'émail ; c) Vue occlusale de rotation de RP3 et LP3 ; d) Vue occlusale et médiale du condyle droit.

belonging to different species that displayed severe dental wear and dentognathic pathologies (Table 1).

4. Description of the findings

4.1. Dental wear

We used Molnar (1971) classification to assess the degree of dental wear. Except for both M3s, the mandibular teeth exhibit severe dental wear accompanied by substantial secondary dentine deposition (Table 2 for the schematic list of scores). The anterior teeth, and the RM1, RM2 and LM2 exhibit complete or almost complete loss of enamel and massive secondary dentine deposition (category 7 and 8). In premolars the enamel is limited to the crown rim and there is extensive secondary dentine deposition (category 6). The occlusal surface of the RM3 and LM3 presents flat morphology and small dentine patches (category 4).

Wear direction is substantially heterogeneous (Table 2). We characterised the direction of wear from buccal and mesial views. From buccal view, 9 teeth display oblique direction. Within the oblique category, 5 (RI1, LI2, RM2, LM2 and RM3) display a distal–mesial direction, whereas mesial–distal direction is recorded in 4 teeth (RI2, RC, LC, LP3). The second most recorded category is the horizontal direction displayed by 3 teeth (LI1, RP3 and LM3).

Finally, rounded wear on the mesial–distal direction, is only recorded in 1 tooth (RM1). From mesial view, the oblique direction is again the most recorded with 6 teeth. Of these, RM2 and LM2 display a buccal–lingual direction and RC, LC, RP3 and LP3 exhibit a lingual–buccal direction. The second most recorded category is rounded with a total of 4 teeth; RI1, RI2, and LI2 follow buccal–lingual direction, and only LI1 presents a mesial–distal direction. Horizontal direction is only displayed by RM3 and LM3 (Fig. 1).

Regarding the occlusal surface form, we recorded two morphologies (Table 2 and Fig. 1). The commonest is the cupped, observed on the posterior dentition (except for the RM1) and LC. It is characterised by a basin–dentine pattern, either on the half or entire occlusal surface. The anterior dentition and the RM1 present rounded morphology.

4.2. Approximal attrition

Hillson's (2008) four-score system was employed to assess the degree of approximal wear. As consequence of the extreme wear, anterior teeth – with the exception of the canines – lack contact with their neighbouring teeth. The highest score (4) is recorded on both surfaces of the four incisors and the RM1. However, RM2 and LM2 display such severe pattern (score 4) only on the mesial surface of the tooth crown. Only the RC – on both surfaces – and LP3 – on the distal surface – exhibited dentine exposure down

Table 1

Comparative sample.

Tableau 1

Comparaison des échantillons.

Chronology	Species	Specimens	Institution
Early Pleistocene	<i>H. sp</i>	ATE9-1	National Research Centre on Human Evolution, Burgos
Middle Pleistocene	<i>H. heidelbergensis</i>	XXI	Centro Mixto UCM-ISCIH de Evolución y Comportamiento Humanos, Madrid
Upper Pleistocene	<i>H. neanderthalensis</i>	La Ferrassie La Chapelle La Quina 5 Tabun 1 Gibraltar 1	Muséum National d'Histoire Naturelle, Paris Muséum National d'Histoire Naturelle, Paris National History Museum, London National History Museum, London
Middle Pleistocene	Archaic <i>Homo sapiens</i>	Broken Hill	National History Museum, London

to the CEJ junction (score 3). Finally, the lowest score (1) is recorded in LC, RM3 and LM3 (mesial surface) and on RM2 (distal surface) where the wear facets are limited to the enamel (Table 2 and Fig. 1).

4.3. Periodontal disease and root exposure

The outer table of the mandible presents severe damage at the level of the RP4, LP3, LM1, LM2 and LM3 that prevented us from scoring changes in the alveolar bone. For the rest, we noted substantial degree of root exposure and signs of periodontal disease in several teeth.

At the level of the RM3 (Fig. 1a and d), there is a space of 2 mm between the distal alveoli wall and the tooth, and on its mesial aspect the alveolar rim is slightly rolled and the lamina is thickened, characteristics that correspond with mild periodontitis (score 2). The distance between the LM3 (Fig. 1a) crown and the alveolar wall is of 2 mm, thus matching the criteria to assess moderate periodontitis (score 3). Despite the bone damage at the vicinity of the LP4 and LM1, there is evidence of pathological processes (hyperlinkPALEVO747FIG0005Fig. 1b and

Fig. 3c). We were unable to obtain the exact dimensions of the original lesion due to the post-mortem fracture; the estimated measures are 11 mm × 10 mm. The alveolar bone at the buccal surface has suffered severe recession almost to the level of the mandibular foramen. In addition, the LP4 alveolus present signs of remodelling with rounded margins and thickening of the outer table (Fig. 3c) that could indicate at least mild periodontitis (score 2). The alveolar rim at the level of the RP3, RC, RI2, LI2 presents a knife-shaped morphology and absence of porous or thickening of the bone (score 1), classified as lack of periodontal disease according to Ogden (2008a,b).

The calculated distance between the AC and CEJ at the location of the RP3, RC, RI2, LI2, and LC ranges from 5 to 10 mm, leaving an extensive vertical root exposure (Figs. 1b–d and 3a).

4.4. Periodontal cysts

As mentioned before, D2600 presents lytic lesions along the mandibular corpus (Fig. 3). At the location of the RM1,

Table 2

Classification of wear categories, wear direction, occlusal surface form and approximal attrition of D2600.

Tableau 2

Classification des catégories d'usure, de direction d'usure, de forme de la surface occlusive et d'attrition approximale pour l'échantillon D2600.

Tooth	Wear category ^a	Wear direction ^a		Occlusal surface form ^a	Approximal attritional facet ^b	
		Buccal view	Mesial view		Mesial	Distal
RM ₃	4	5	6	3	1	–
RM ₂	7	5	3	4	4	1
RM ₁	8	8	7	6	4	4
RP ₃	6	6	2	4	1	1
RC,	7–8	4	2	6	3 ^c	2–3 ^d
RI ₂	8	4	7	6	4	4
RI ₁	8	5	7	6	4	4
LI ₁	8	6	8	6	4	4
LI ₂	8	5	7	6	4	4
LC,	7	4	2	3	1	1 ^e
LP ₃	6	4	2	4	1	3
LM ₁						
LM ₂	7	5	3	3	4	1
LM ₃	4	6	6	3	1	–

^a Molnar (1971).^b Hillson (2008).^c at least degree 1.^d at least degree 2.^e due to the heavy attrition, this value is an estimation.

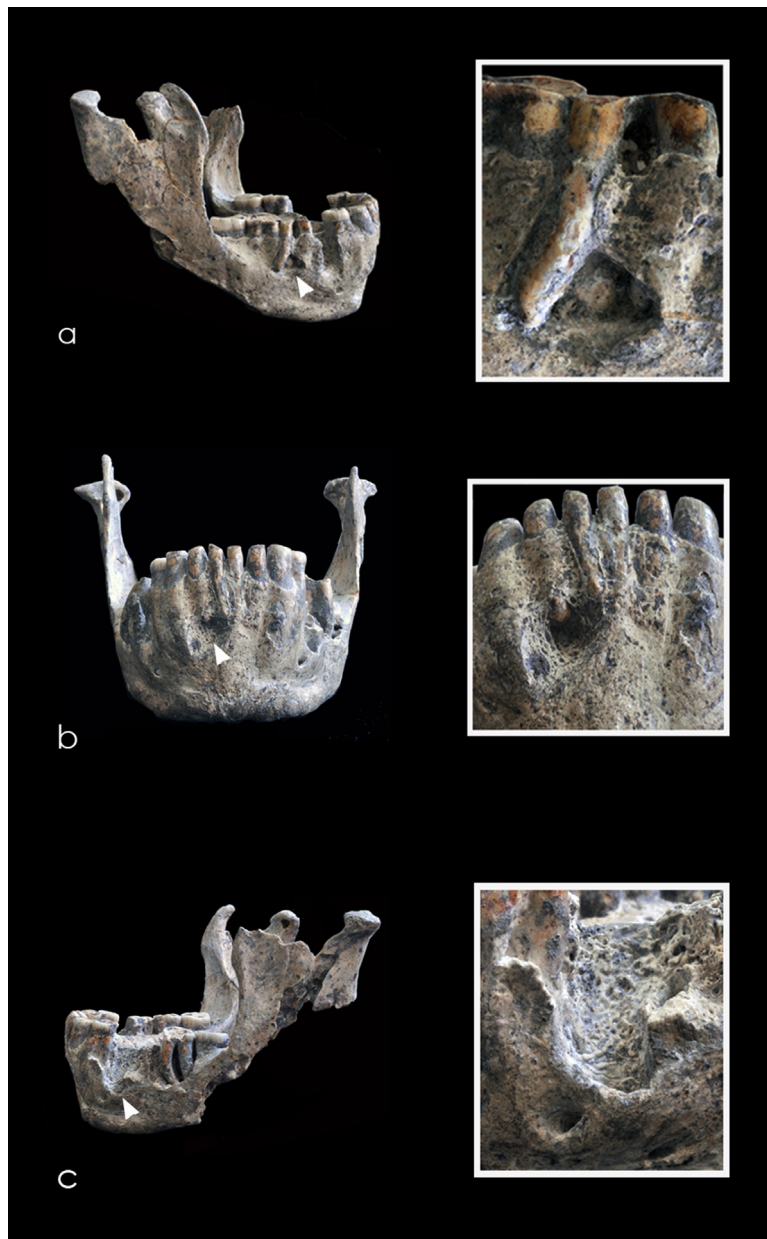


Fig. 3. D2600 lytic lesions. a) Right view; b) Anterior view; c) Left view.

Fig. 3. Lésions lytiques de D2600. a) Vue droite ; b) Vue antérieure ; c) Vue gauche.

the osteoclast activity has created a 14 mm × 10 mm lesion of elliptical shape that leaves exposed the bucco-distal root, and the apexes of the mesio-buccal root and of the lingual root. The margins of the lesion are rounded, especially on its inferior border, and the external table is thickened (Fig. 3a). The osteolytic lesion at the RI2 (10 mm × 8 mm) presents a circular morphology and displays rounded and porous margins leaving the apex exposed. The lesion has extended towards the inferior border of the mandible leaving the cancellous bone exposed (Fig. 3b). In addition to the post-depositional fracture and the bone recession affecting the region of LP4-LM1, at the level of the LM1 mesial root on occlusal view there is an osteolytic lesion (5 mm × 3 mm)

that presents funnel-shape inner morphology and smooth margins (Fig. 1a). Except for the last, all the lesions display morphology and dimensions coincident with chronic cysts.

4.5. Tooth fracture

We identified five teeth – RM1, RC, RP3, LP3 and LM2 – with some amount of enamel breakage. Due to the degree of enamel involvement, all are categorised as fractures (see Patterson, 1984). RM1 suffered a breakage on its lingual surface that affected the crown and both radicals, causing significant loss of enamel, cementum and dentine tissues. We estimated a vertical root loss of 3 mm in the

mesio-lingual radical and of 6 mm on the disto-lingual radical. The remaining surface presents a polished and rounded morphology (Figs. 1b, d and 2c) coincident with a pre-mortem fracture. LP3 presents two enamel fractures (Fig. 2b). The enamel on the mesial surface, posterior to the approximal facet with the canine, presents a change of colouration and sharp margins indicative of a peri- or post-mortem event. On the distal surface, the enamel breakages are at the margins of the approximal facet. At the anterior margin, the edges are sharp coincident with a peri- or post-mortem fracture; whereas at the posterior margin the edges are polished, indicating a pre-mortem event. In the RC, we observed small breakage on the disto-buccal margin of the enamel rim and a breakage on the disto-lingual angle of the crown (Fig. 2b). The RP3 presents enamel breakage at the mesio-lingual surface of the crown, located posterior to the contact facet with the canine (Fig. 2b). The enamel breakage of the LM2 affects the bucco-distal surface (Fig. 1b, d). The margins of these breakages (RC, RP3, and LM2) exhibit sharp and straight morphology, lack of polished surfaces and change in enamel colouration, suggesting peri- or post-mortem events. In total, there are 2 pre-mortem and 5 peri- or post-mortem fractures.

4.6. Alveolar dehiscence and fenestrations

We recorded three dehiscences – RI1, LI1 and LP3 – and two fenestrations – LI2 and LC – that leave the buccal surface of the roots denuded, either partially or in its totality (Figs. 1b–d and 3). The root of RI1 is exposed 17 mm from the alveolar margin down to the apex. As for the LI1, the root surface is exposed 10 mm from the alveolar margin, although it does not involve the apex. The middle 1/3 of the LI2 and LC root are exposed due to a flaking of 3 and 5 mm respectively. Finally, the mesial root of the LP3 is completely exposed (13 mm) from the alveolar margin down to the apex.

4.7. Tooth rotation

Both P3s exhibit signs of mesial rotation. RP3 has rotated 90°, whereas LP3 exhibits a lower value, approximately 80° (Fig. 2c). The anticlockwise movement is also evinced for the formation of new contact facets on both enamel surfaces (Fig. 2b, c).

4.8. Degenerative joint disease

There are noticeable metric and morphological differences between the right and left mandibular condyles (Fig. 2a, d). We obtained measurements on the right and left condyles of 25 mm and 25 mm medial–lateral diameter, and 9.5 mm and 15 mm antero-posterior diameter, respectively. Morphologically, the articular surface of the left condyle exhibits bone remodelling and porosity, loss of curvature height on antero–posterior direction and exposure of the cancellous bone on the lateral side (Fig. 2a, d). All the signs identified on the left condyle, compared to the right, are consistent with temporomandibular arthropathy (TMJ).

4.9. Mandibular ramus lesion

There is a hole of 7 mm × 5 mm located at the *pterygoid fovea* of the right mandibular ramus (Figs. 1b, 2c and 3d). Although the rims are eroded there are not porosity around the margins, signs of remodelling or osteoblastic process.

5. Summary of the general pathology

In this individual, wear has proceeded to such an extreme degree that no enamel is left on the occlusal surfaces of the majority of teeth. The pulp chamber was exposed and secondary dentine was then deposited to seal the pulp chamber and allow chewing function. This sealing process also helps to avoid pulpal infection but, at least in two cases, the bacterial infection occurred. Bacteria spread along the root canals, pulp undergoes necrosis and the tooth becomes non-vital. The infective products remain in the bone, creating a space-occupying lesion that eventually drained the debris through the buccal surface of the alveolar bone as it is thinner. This infective process resulted in the cysts observed on the buccal surface of D2600 mandibular bone at the location of the RM1 and RI2. Infective agents would have also caused the periodontal disease observed at some locations of the alveolar bone. At the same time, teeth would have undergone continuous eruption to compensate for the extreme dental wear. Another consequence of the severe dental wear is the pre-mortem enamel fractures as thinning of the enamel tissue makes it more brittle and susceptible of fracture. In turn all these processes would have enhanced the development of the left condyle TMJ.

6. Discussion

The enamel morphology resultant from the wear process can reflect dietary preferences and behavioural patterns of hominin species (e.g., Fiorenza et al., 2011; Hinton, 1981; Teaford and Ungar, 2000; Ulhaas et al., 2007; Ungar, 1994; Ungar and Grine, 1991). Extreme dental wear can jeopardize the individual's survival as it might lead to poor nutritional intake, disease and eventually to death (Elgart, 2010; Lovell, 1991). The degree and rate of enamel wear highly depends on several factors such as occlusal variation, environment or behavioural activities – pre- and para-masticatory functions (Addy and Shellis, 2006).

Although Pontzer et al. (2011) concluded that there were no significant differences between the dietary habits of the Dmanisi individuals and the African predecessors, we have not found any specimen displaying a similar wear pattern as that exhibited by D2600. All the individuals of the comparative sample – Skull 5, Gibraltar 1, La Ferrassie 1, La Chapelle – exhibit severe although similar degree of dental wear among the dentition (Tables 3–8 and Fig. 4). We have found that the extreme and rounded wear exhibited by D2600 anterior teeth would be similar to that found in chimpanzees and humans in relation to food preparation activities such as gripping and stripping (e.g., Elgart, 2010; Ungar and Grine, 1991; Wolpoff, 1999). Anterior teeth from chimpanzees exhibit significant dental wear compared with posterior teeth, most likely as a

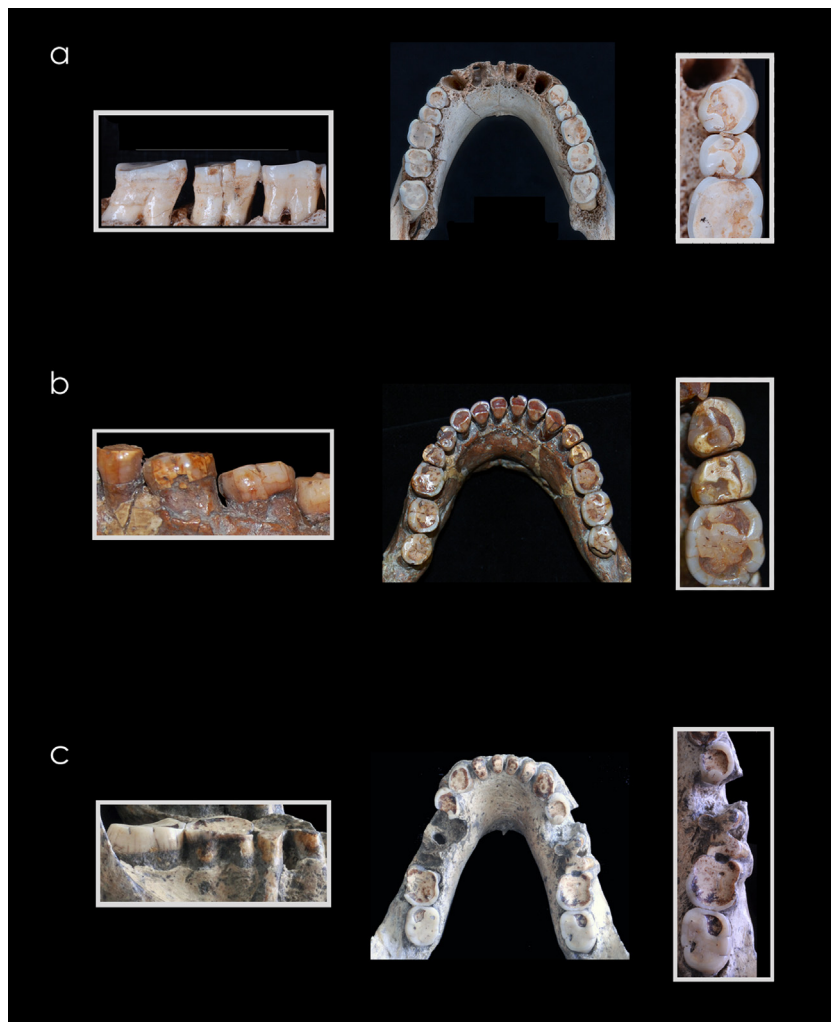


Fig. 4. Mesial drift of the anterior dentition in three fossil specimens. a) Individual XXI (*H. heidelbergensis*, Atapuerca); b) Tabun 1 (*H. neanderthalensis*, Tabun); c) D2600 (*H. georgicus*, Dmanisi).

Fig. 4. Déviation médiale de la dentition antérieure dans trois spécimens fossiles. Individu XXI (*H. heidelbergensis*, Atapuerca); b) Tabun 1 (*H. neanderthalensis*, Tabun); c) D2600 (*H. georgicus*, Dmanisi).

consequence of food preparation activity (Dean et al., 1992; Elgart, 2010; Lovell, 1991; Morgan and Sanz, 2006). We believe that the unbalanced degree of wear between the anterior and posterior dentition is similar to that found in D2600. When severe wear reduces teeth to stumps, these

are unable to process food and longer chewing process is required (Elgart, 2010). Thus, the polished appearance of the anterior dentition is more likely due to food preparation activities and prolonged mulling. The posterior wear pattern in D2600 is characterised by dentine basin and

Table 3

Classification of wear categories, wear direction, occlusal surface form and approximal attrition of ATE9-1 (*Homo sp.*).

Tableau 3

Classification des catégories d'usure, de direction d'usure, de forme de la surface occlusive et d'attrition approximale pour l'échantillon ATE9-1 (*Homo sp.*).

Tooth	Wear category ^a	Wear direction ^a		Occlusal surface form ^a	Approximal attritional facet ^b	
		Buccal view	Mesial view		Mesial	Distal
RI ₂	7	2	4	2	3	3
RC,	7	4	4	2	2	2
LC,	7	4	4	–	–	2
LP ₄	5	4	4	3	1	1

–: data could not be recorded.

^a : Molnar (1971); ^b: Hillson (2008).

Table 4Classification of wear categories, wear direction, occlusal surface form and approximal attrition of La Chapelle-aux-Saints (*Homo neanderthalensis*).**Tableau 4**Classification des catégories d'usure, de direction d'usure, de forme de la surface occlusive et d'attrition approximale pour l'échantillon de La Chapelle-aux-Saints (*Homo neanderthalensis*).

Tooth	Wear category ^a	Wear direction ^a		Occlusal surface form ^a	Approximal attritional facet ^b	
		Buccal view	Mesial view		Mesial	Distal
RP ⁴	8	8	8	6	4	4
RM ³	5	6	1	1	1	
LP ₃	7	4	2	2	4	4

^a Molnar (1971)^b Hillson (2008).

enamel rim, except for both M3s. The unusual wear gradient between the M3 with regard to the M1 and M2 cannot solely be attributed to the difference in eruption times as it has not been recorded in any of the individuals of the comparative sample, which include also individuals of younger age than D2600. We suggest that the wear pattern of the posterior dentition would be similar to that of folivorous species, in particular to gorillas, and resemble that of *Paranthropus*. This type of food is more abrasive because of the phytoliths contained and the dust or soil

particles adhered to the food (Elgart, 2010). Due to this type of food, gorillas exhibit extreme posterior dental wear. Gorillas, as ruminants, exhibit a rapid molar wear that creates a central dentine basin and the remaining enamel would act as cutting blades (Fig. 5). This pattern is thought to benefit the ingestion of folivorous diets (Dean et al., 1992; Elgart, 2010; Lovell, 1991; Lucas, 2004; Morgan and Sanz, 2006). According to Ulhaas et al. (2007) the pattern of molar wear recorded in *Paranthropus* – rapid enamel reduction and sharp edges – would result from a long chewing

Table 5Classification of wear categories, wear direction, occlusal surface form and approximal attrition of La Ferrassie 1 (*Homo neanderthalensis*).**Tableau 5**Classification des catégories d'usure, de direction d'usure, de forme de la surface occlusive et d'attrition approximale pour l'échantillon de la Ferrassie 1 (*Homo neanderthalensis*).

Tooth	Wear category ^a	Wear direction ^a		Occlusal surface form ^a	Approximal attritional facet ^b	
		Buccal view	Mesial view		Mesial	Distal
RM ³	7	6	6	2	4	
RM ²	7	6	3	3	2*	4
RM ¹	8	4	6	6	4	4
RP ⁴	8	6	6	2	4	4
RP ³	8	5	2	2	4	4
RC*	8	4	3	3–4	4	4
RI ²	8	4	3	3–4	4	4
RI ¹	7	4	3	2	4	4
LI ¹	7	5	3	3–4	4	4
LI ²	7	6	3	3–4	4	4
LC*	8	6	3	3	4	4
LP ³	8	5	6	3	4	4
LP ⁴	8	4	3	3	4	4
LM ¹	8	4	6	3	4	3*
LM ²	7	5	3	3	3*	2*
LM ³	5	5	3	3	2*	
RM ₃	7	4	2	2	3*	
RM ₂	7	4	2	2	4	4
RM ₁	7	4	6	2	4	4
RP ₄	8	5	6	2	4	4
RP ₃	8	5–6	6	2	4	4
RC,	8	4	7	2–6	4	4
RI ₂	8	4	7	6	4	4
RI ₁	8	4	7	6	4	4
LI ₁	8	4	7	6	4	4
LI ₂	8	4	2–7	2	4	4
LC,	8	6	6	3	4	4
LP ₃	8	6	6	2	4	4
LP ₄	8	6	2–7	6	4	4
LM ₁	8	2–8	2	3	4	4
LM ₂	8	2–8	6	2	4	4
LM ₃	7	4	2	2	4	

* due to tooth contact, we provide an approximate score based on the thinning of the enamel rim on occlusal view.

^a Molnar (1971).^b Hillson (2008).

Table 6Classification of wear categories, wear direction, occlusal surface form and approximal attrition of La Quina (*Homo neanderthalensis*).**Tableau 6**Classification des catégories d'usure, de direction d'usure, de forme de la surface occlusive et d'attrition approximale pour l'échantillon de La Quina (*Homo neanderthalensis*).

Tooth	Wear category ^a	Wear direction ^a		Occlusal surface form ^a	Approximal attritional facet ^b	
		Buccal view	Mesial view		Mesial	Distal
RM ³	4	6	2	2	1*	
RM ²	4	5	2	2	1*	1*
RM ¹	5	4	3	3	1*	1*
RP ⁴	3	4	2	2	1*	1*
RP ³	3	4	2	2	1*	1*
RC	5	6	2	2	1	1*
RI ²	–	–	–	–	2	1*
RI ¹	6	6	6	2	1	1
LI ²	6	6	2	2	1	1*
LC	5	6	2	2	1*	1*
LP ³	3	6	2	2	1*	1*
LP ⁴	3	4	2	2	1*	1*
LM ¹	5	4	2	3	1*	1*
LM ²	4	6	6	2	1*	1*
LM ³	4	6	6	2	1*	
RM ₃	5	5	3	2	–	
RM ₂	5	6	3	3	1*	1*
RM ₁	5	6	3	3	1*	1*
RP ₄	4	6	6	1	1*	1*
RP ₃	4	4	2	1	1	1*
LC	5	6	2	2	2	1*
LP ₃	4	6	2	1	1*	1*
LP ₄	4	6	3	2	1*	1*
LM ₁	5	6	3	3	1*	1*
LM ₂	4	6	3	3	1*	1*
LM ₃	3	6	6	2	1*	

* due to tooth contact, we provide an approximate score based on the thinning of the enamel rim on occlusal view.

^a : Molnar (1971).^b Hillson (2008).

process of tough foods, such as tubers, that would include soil particles.

In great apes, hominins and modern humans severe wear has been shown to lead to dental migration and disease (e.g., Cousins, 1988; Crovella and Ardito, 1994; Dean et al., 1992; Kaifu et al., 2003). *Continuous eruption* is an adaptive mechanism associated to enamel wear that maintains and enables efficient masticatory function through life. It is evinced by the increased distance between the AC and the CEJ, particularly in absence of pathological signs, and the preservation of the alveolar crest height (e.g., d'Incau et al., 2012; Kaifu et al., 2003; Levers and Darling, 1983). In their study, Dean et al. (1992) recorded lack of generalised periodontal disease and an AC-CEJ distance between 3 and 8 mm in the mandibular bones of great apes. The authors concluded that *continuous eruption* would be the most likely cause for the recorded distance. Similar results have been reported for hominins and modern humans (e.g., Hylander, 1977; Martínón-Torres et al., 2011; Whittaker et al., 1990). Thus, our results would also suggest *continuous eruption* as the likely cause of the tooth extrusion in those locations – RP3, RC, RI2, LI2, LC – where no signs of infection such as periodontal disease or periodontal cysts were recorded. However, despite the lack of generalised periodontal disease, this individual would have probably suffered recurrent inflammation of the gums (gingivitis) as it normally occurs together with periodontal disease. Approximal attrition is a process resulting from

the forces generated during mastication; individuals with stronger or more frequent bites forces show higher rates of approximal wear (Galbany et al., 2010; Smith, 2011). In turn, *mesial drift* compensates for this enamel loss (e.g., d'Incau et al., 2012; Kaifu et al., 2003; Ten Cate, 1998). Fayad et al. (2004) concluded that M1 and M2 are more mesially inclined in those individuals with an erupting or fully erupted M3. This anterior migration has been recorded in baboons (Galbany et al., 2010) and humans [e.g., *Homo floresiensis* (Jungers and Kaifu, 2011)]. Compared to our *Homo heidelbergensis* – Sima de los Huesos – and Neanderthal – Tabun 1, La Quina and Ferrassie 1 – samples (Fig. 4), and the two younger specimens of Dmanisi – D2735 and D211 – Margvelashvili et al. (2013) Figs. 2, S3 and S4], D2600 displays a minimum or even null mesial drift in relation to the severe dental wear. Thus, we suggest that this lack of anterior migration of posterior teeth cannot be related to eruption timing; otherwise it could indicate that the wear process was too rapid to enable the mesial drift response.

Fenestrations and dehiscence can be the consequence of excessive occlusal forces, thin alveolar bone or tooth misalignment (Nimigean et al., 2009; Rupprecht et al., 2001). This condition is fairly common in maxillary bones of gorillas, although less common in chimpanzees (Dean et al., 1992). The bulky appearance of D2600 roots together with the thin alveolar and advanced wear could be probable causes for the fenestrated and dehiscenced roots. In the

Table 7Wear categories; wear direction, occlusal surface form and approximal facets of Tabun 1 (*Homo neanderthalensis*).**Tableau 7**Catégories d'usure, de direction d'usure, de forme de la surface occlusive et de facettes approximale pour l'échantillon de Tabun 1 (*Homo neanderthalensis*).

Tooth	Wear category ^a	Wear direction ^a		Occlusal surface form ^a	Approximal attritional facet ^b	
		Buccal view	Mesial view		Mesial	Distal
RM ²	3	2	6	1	1*	1
RM ¹	4–5	2	6	1	1*	1
RP ⁴	3	2	4	2	1*	1*
RP ³	4	2	6	2	1*	1*
RC ^c	5	2	6	2	1*	1*
RI ²	–	–	–	–	–	–
RI ¹	6	2	6	2	2*	1
LI ¹	6	2	6	2	2*	2*
LI ²	6	2	6	2	2*	2*
LC ^c	5	2	6	2	–	1
LP ³	–	–	–	–	–	–
LP ⁴	2–3	2	6	1	1	1
LM ¹	3	2	5	1	2	2
LM ²	2–3	2	6	1	1*	1*
LM ³	2	2	6	1	1*	–
RM ₃	2	3	6	1	1*	–
RM ₂	4	3	6	1	1*	2*
RM ₁	5	3	4	1	2*	1*
RP ₄	3	6	6	2	3*	3*
RP ₃	3–4	6	4	2	1*	3*
RC _c	5–6	6	4	2	2*	1*
RI ₂	5–6	6	6	2	3–4*	3*
RI ₁	6	6	6	2	3–4*	3–4*
LI ₁	6	6	6	2	3–4*	3–4*
LI ₂	5–6	6	6	2	3–4*	3*
LC _c	5–6	6	4	2	2*	1*
LP ₃	3–4	6	6	2	1*	2*
LP ₄	3	6	6	2	3*	3*
LM ₁	4–5	3	6	2	1*	2*
LM ₂	3	3	6	2	2*	1*
LM ₃	2	3	5	1	1*	–

^a due to tooth contact, we provide an approximate score based on the thinning of the enamel rim on occlusal view.^a Molnar (1971).^b Hillson (2008).

case of RI1, infectious process is the most likely cause since a major cyst is affecting the RI2 vicinity. However, future studies with CT images of the specimen can help to support or disregard this claim.

Dental wear is the primary cause for the development of periodontal abscess, although tooth fracture can also be a likely cause (e.g., Gracia-Téllez et al., 2013; Lebel and Trinkaus, 2002; Legge, 2012; Lovell, 1991; Tappen, 1985).

Table 8Classification of wear categories, wear direction, occlusal surface form and approximal attrition of Broken Hill (archaic *Homo sapiens*).**Tableau 8**Classification des catégories d'usure, de direction d'usure, de forme de la surface occlusive et d'attrition approximale pour l'échantillon de Broken Hill (*Homo sapiens* archaïque).

Tooth	Wear category ^a	Wear direction ^a		Occlusal surface form ^a	Approximal attritional facet ^b	
		Buccal view	Mesial view		Mesial	Distal
RM ³	–	–	–	–	–	–
RM ²	2–3	2	4	–	2	–
RM ¹	2–3	2	4	–	–	–
RI ¹	7	2	6	1	4	4
LI ¹	7	2	6	1	4	4
LI ²	7	2	5	1	4	–
LC ^c	6	2	5	2	–	–
LP ³	6–7	2	4	–	–	–
LM ²	2–3	2	4	–	–	–
LM ³	2–3	2	6	3	–	–

–: data could not be recorded due to the damage of the tooth crowns.

^a Molnar (1971).^b Hillson (2008).

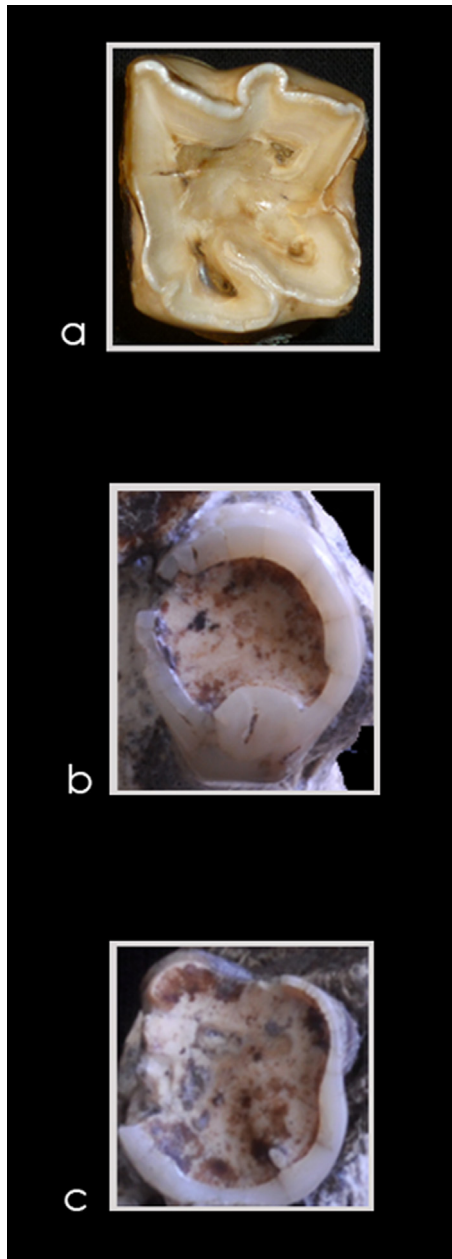


Fig. 5. Occlusal wear of an herbivore molar (a) and the RP3 (b) and RM1 (c) of D2600 (credits for a): D. Arceredillo-Alonso).

Fig. 5. Usure occlusale d'une molaire d'herbivore (a) et RP3 (b) et RM1 (c) de D2600 (autorisation pour a): D. Arceredillo-Alonso).

Pulp infection produces necrosis and the tooth becomes non vital. If it persists, this will result in bone destruction and a probable ante-mortem tooth loss (ATL) (e.g., [Dias and Tayles, 1997](#); [Ogden, 2008a,b](#)). Our results for RM1 and RI2 would suggest dental wear in relation to a fibrous and abrasive diet for the abscess formation. The bone resorption at the vicinity of the LP4-LM1 was more likely caused by an infectious episode such as an abscess. However, we cannot ascertain if the bone resorption would have caused ATL, since the posterior table preserves its height and the

teeth could be yet in place held by soft tissues. In disagreement with [Margvelashvili et al. \(2013\)](#), we believe that D2600 bone resorption differs from that of the D3900 since edentulous individuals exhibit bone resorption all the way down to the mental foramen on both the buccal and the lingual surfaces ([Cawood and Howell, 1988](#)) as seen in La Chapelle (personal observation). However, in D2600 the height of the lingual crest is preserved. In their study, [Lordkipanidze et al., 2005](#) do not suggest an aetiology for the ATL and the extensive bone resorption of D3900 and D3444. According to [Dias and Tyles \(1997\)](#), chronic periodontal disease produces the loss of bone from the alveolar margin, in contrast to the apical resorption in periodontal cysts. Thus, chronic periodontal disease can be suggested as a probable cause of the D3900/D3444 ATL.

Two factors are considered to cause enamel fractures: severe wear and the use of teeth in para- and/or pre-masticatory activities ([Constantino et al., 2010](#); [Scott and Winn, 2011](#)). The thinning of the tissue would be more prone to breakage during the mastication of abrasive and fibrous foods with adhered soil particles and during para- and/or pre-masticatory activities.

Higher tooth rotation than 30° is considered to be abnormal; authors refer to genetic and environmental factors – missing teeth, infection or food impaction – as the causes ([Harris and Corruccini, 2008](#); [Natsume et al., 2006](#); [Primožič et al., 2012](#)). Contrary to the genetic cause suggested for the maxillary rotation of LP4 from D2700 individual ([Martín-Torres et al., 2008](#)), LP4 from Aragón 21 ([Smith, 1977](#)) and bilateral P4s of LB1 ([Brown et al., 2004](#)), we believe that D2600 bilateral tooth rotation would be the consequence of environmental factors in order to enable masticatory function.

Severe malocclusion, related to severe wear and/or continuous eruption, and/or ATL are factors that damage the stable “centric” occlusal position of the mandible causing irregular loop-shaped chewing movements. This masticatory malfunction with time will develop in osteoarthritis of the mandibular condyles ([Langsjoen, 1998](#); [LeResche, 1997](#)). The left mandibular condyle of D2600 presented the characteristic signs of TMJ. There is a likely correlation between extreme dental wear, continuous eruption, tooth rotation and possibly ATL and the development of TMJ in D2600 individual. Factors also observed in other fossil individuals such as Skull 5 ([Gracia-Téllez et al., 2013](#)), La Chapelle ([Tappen, 1985](#)) and La Ferrassie ([Wallace, 1975](#)).

The hole seen at the right ramus is located at the *pterygoid fovea*. It bears the part of the *lateral pterygoid* muscle, a guiding muscle of the mandibular joint ([Platzer, 2004](#)). Studies found an association between the *lateral pterygoid* muscle and TMJ disorder ([McNeill et al., 1990](#); [Murray et al., 2001](#)). We believe that the loss of bone at D2600 right ramus is more likely due to diagenetic processes, since there is no sign of TMJ in the right condyle, and muscle disorders (hypertrophy, atrophy or contracture) do not enhance osteoclastic activity, otherwise blastic activity ([Yang, 2002](#)).

Despite all these pathological processes, there is evidence of the chronicity of the lesions, thus implying the survival of the individual for a certain period of time. Other

hominins with pervasive dento-gnathic lesions such as ATE9-1 from Atapuerca-Sima de Elefante site (Martín-Torres et al., 2011), La Chapelle-aux-Saints (Tappen, 1985; Trinkaus, 1985) and D3900/D3444 (Lordkipanidze et al., 2005) have also shown signs of endurance. The question arising is if collaboration within the group was necessary for the survival of these individuals (e.g., DeGusta, 2003; Gracia et al., 2009).

Interestingly, despite the severity of the pathological processes observed in D2600, the morphology of the mandible has not been significantly altered because the alveolar crest was minimally remodelled. According to Margvelashvili et al. (2013), in keeping with compensatory eruption of the teeth, both the corpus and the symphysis of D2600 would have increased their height. However, compensatory eruption produces the protrusion of teeth through the axial movement of the dental pieces, hyperproduction of cementum and/or remodelling of the socket, but not by increasing the alveolar crest height (e.g., Kaifu et al., 2003; Levers and Darling, 1983; Ogden, 2008a,b; Ten Cate, 1998; Whittaker et al., 1990). On the contrary, most of the compensatory mechanisms related with occlusal adaptation provoke remodelling of the alveolar rim by reducing (but not increasing) its height, such as *compensatory receding bone* (Clarke and Hirsch, 1991; Hillson, 2008). Finally, it is generally accepted that alveolar bone heights show no significant change (or a slight increase if any) with wear or age during adulthood (e.g., Hylander, 1977; Kaifu et al., 2003; Levers and Darling, 1983; Newman and Levers, 1979; Tallgren and Solow, 1991; Whittaker et al., 1990), and never at such degree as observed within the Dmanisi mandibles. Thus, our study would not be in support of attributing the mandibular shape differences to the dental pathologies and/or their compensatory mechanisms as stated by Margvelashvili et al. (2013). In addition, and despite the greater degree of wear, we have not observed mesial drift in D2600 compared to the younger D2735 and D211. Finally, we do not agree that the ATL and bone resorption recorded in D3900/D3444 is the same as the recorded in D2600 since the lingual wall is preserved. As pointed out by Cawood and Howell (1988), in edentulous individuals we should expect alveolar resorption on both surfaces – buccal and lingual – down to the mental foramen and unlike D2600.

7. Conclusions

The study of the mandibular bone D2600 belonging to *H. georgicus* from Dmanisi (Georgia) revealed severe and extensive wear that enhanced other pathological processes. Thus, in relation to the wear process we identify signs of dental compensation (axial movement), tooth rotation, enamel fractures, and degenerative and infectious processes. We hypothesize that the principal and primary cause of the type and degree of dental wear of the D2600, similar to that of chimpanzees and gorillas, would be the intake of abrasive and fibrous foods such as plants and fruits. These dietary habits require pre-/paramasticatory preparation, such as gripping and stripping that is reflected in the wear pattern of the anterior dentition. Moreover, this food would also be the origin of

the wear pattern observed in the posterior dentition. It is difficult to ascertain the chronology of the events, since some of the identified signs are cause and consequence of the same pathological process. This study contributes to increase the knowledge about pathological record and the state of hominins health during Pleistocene. Finally, we believe that despite the lesions, the morphology of the mandible was not significantly altered. So pathological changes cannot be invoked as the mechanism explaining the particular morphology of D2600.

Acknowledgments

The authors would like to acknowledge David Lordkipanidze and all the colleagues and friends from the Dmanisi Research team for providing access to the material and for their dedicated work and assistance during all these years of collaboration. This research was carried out under the Cooperation Treaty between Spain and the Republic of Georgia, hosted by the Fundación Duques de Soria and the Georgian National Museum. We thank the editor and two anonymous reviewers for their constructive comments, which helped us to improve the manuscript. Referee 2 provided us particularly enlightening insights regarding wear pattern and physiopathology of the alveolar crest changes. We also thank Dr. Kaifu from University of Tokyo for his helpful comments. Special thanks to the colleagues from the Atapuerca research team from the Centro Mixto UCM-ISCIH de Investigación sobre Evolución y Comportamiento Humanos, Philippe Menecier, Aurélie Fort and Véronique Laborde from the Musée de l'Homme (Paris) and to Rob Kruszynski from The Natural History Museum (London). Thanks to Diego Arceredillo Alonso for providing Fig. 5a and for his valuable insights on herbivore enamel wear, and to José Manuel de la Cuétara for his comments. This research was supported with funding from the Dirección General de Investigación of the Spanish Ministerio de Educación y Ciencia (MEC), Project No. CGL2009-12703-C03-01, 02 and 03 and from Junta de Castilla y León Projects No. BU005A09 and GR249, Fundación Duques de Soria, Synthesys (Synthesis of Systematic Resources) Grant and Programa Jóvenes Excelentes Grant (Fundación Gutiérrez Manrique-Obra Social Caja de Burgos). Fieldwork at Atapuerca is supported by the Consejería de Cultura y Turismo of the Junta de Castilla y León and the Fundación Atapuerca. Laura Martín-Francés is beneficiary of a predoctoral grant of the Fundación Duques de Soria. Ana Gracia-Téllez has a Contract-Grant from the Ramón y Cajal Program, RYC-2010-06152.

References

- Addy, M., Shellis, R.P., 2006. *Interaction between attrition, abrasion and erosion in tooth wear*. In: Lussi, A. (Ed.), *Dental erosion from diagnosis to therapy*. Karger, Basel, pp. 17–31.
- Begg, P.R., 1954. *Stone age man's dentition: with reference to anatomically correct occlusion, the etiology of malocclusion, and a technique for its treatment*. *Am. J. Orthod.* 40, 517–531.
- Bräuer, G., Schultz, M., 1996. *The morphological affinities of the Plio-Pleistocene mandible from Dmanisi, Georgia*. *J. Hum. Evol.* 30, 445–481.

- Brown, P., Sutikna, T., Morwood, M.J., Soejono, R.P., Jatmiko, Wayhu Sap-
tomo, E., Awe Due, R., 2004. A new small-bodied hominin from the
Late Pleistocene of Flores, Indonesia. *Nature* 431, 1055–1061.
- Cawood, J.I., Howell, R.A., 1988. A classification of the edentulous jaws.
Int. J. Oral Maxillofac. Surg. 17, 232–236.
- Clarke, N.G., Hirsch, R.S., 1991. Physiological, pulpal and periodontal fac-
tors influencing alveolar bone. In: Kelley, M.A., Larsen, C.S. (Eds.),
Advances in dental anthropology. John Wiley & Sons, Inc., New York,
pp. 241–266.
- Constantino, P.J., Lee, J.J.-W., Chai, H., Zipfel, B., Ziscovici, C., Lawn, B.R.,
Lucas, P.W., 2010. Tooth chipping can reveal the diet and bite forces
of fossil hominins. *Biol. Lett.* 6, 826–829.
- Cousins, D.C., 1988. Dental disease in the gorilla. *Int. Zoo News* 35, 10–18.
- Crovella, S., Ardito, G., 1994. Frequencies of oral pathologies in a sample
of 767 non-human primates. *Primates* 35, 225–230.
- Davies, R.M., Downer, M.C., Hull, P.S., Lennon, M.A., 1974. Alveolar defects
in human skulls. *J. Clin. Periodontol.* 1, 107–111.
- Dean, M.C., Jones, M.E., Pilley, J.R., 1992. The natural history of tooth wear,
continuous eruption and periodontal disease in wild shot great apes.
J. Hum. Evol. 22, 23–39.
- DeGusta, D., 2003. Aubesier 11 is not evidence of Neanderthal conspecific
care. *J. Hum. Evol.* 45, 91–94.
- d’Incau, E., Couture, C., Maureille, B., 2012. Human tooth wear in the past
and the present: tribological mechanisms, scoring systems, dental and
skeletal compensations. *Arch. Oral Biol.* 57, 214–229.
- Dias, G., Tayles, N., 1997. “Abscess cavity” – a misnomer. *Int. J. Osteoar-
chaeol.* 7, 548–554.
- Elgart, A.A., 2010. Dental wear, wear rate, and dental disease in the African
apes. *Am. J. Primatol.* 72, 481–491.
- Fayad, J.B., Levy, J.C., Yazbeck, C., Cavezian, R., Ea, C., 2004. Eruption of third
molars: relationship to inclination of adjacent molars. *Am. J. Orthod.
Dentofacial. Orthop.* 125, 200–202.
- Fiorenza, L., Benazzi, S., Tausch, J., Kullmer, O., Bromage, T.G., Schrenk, F.,
2011. Molar macrowear reveals Neanderthal eco-geographic dietary
variation. *PLoS ONE* 6, 14769.
- Gabunia, L.K., Vekua, A., 1995. A Plio-Pleistocene hominid from Dmanisi,
East Georgia, Caucasus. *Nature* 373, 509–512.
- Gabunia, L.K., Vekua, A., Lordkipanidze, D., Swisher III, C.C., Ferring, R.,
Justus, A., Nioradze, M., Tvalcridze, M., Anton, S., Bosinski, G.C., Jöris,
O., de Lumley, M.A., Majusuradze, G., Mouskhelishvili, A., 2000. Ear-
liest Pleistocene hominid cranial remains from Dmanisi, Republic of
Georgia. *Science* 288, 1019–1025.
- Gabunia, L., de Lumley, M.A., Vekua, A., Lordkipanidze, D., de Lumley, H.,
2002. Découverte d’un nouvel hominidé a Dmanissi (Transcaucasie,
Géorgie). *C. R. Palevol.* 1, 242–253.
- Galbany, J., Dotras, L., Alberts, S.C., Pérez-Pérez, A., 2010. Tooth size var-
iation related to age in Amboseli baboons. *Folia Primatologica* 81,
348–359.
- Gracia, A., Arsuaga, J.L., Martínez, I., Lorenzo, C., Carretero, J.M., Bermúdez
de Castro, J.M., Carbonell, E., 2009. Craniosynostosis in the Middle
Pleistocene human Cranium 14 from the Sima de los Huesos, Atapuerca,
Spain. *Proc. Natl. Acad. Sci. U S A* 106, 6573–6578.
- Gracia-Téllez, A., Arsuaga, J.L., Martínez, I., Martín-Francés, L., Martínón-
Torres, M., Bermúdez de Castro, J.M., Bonmatí, A., Lira, L., 2013. Orofacial
pathology in *Homo heidelbergensis*: the case of skull 5 from the
Sima de los Huesos site (Atapuerca, Spain). *Quat. Int.* 295, 83–93.
- Harris, E.F., Corruccini, R.S., 2008. Quantification of dental occlusal varia-
tion: a review of methods. *IJDA* 21, 1–11.
- Hillson, S., 2008. Dental Pathology. In: Katzenberg, M.A., Saunders, S.R.
(Eds.), *Biological anthropology of the human skeleton*. John Wiley &
Sons Inc., New Jersey, pp. 301–340.
- Hinton, R.J., 1981. Form and patterning of anterior tooth wear among
aboriginal human groups. *Am. J. Phys. Anthropol.* 54, 555–564.
- Hylland, W.L., 1977. Morphological changes in human teeth and jaws in
a high-attrition environment. In: Dahlberg, A.A., Graber, T.M. (Eds.),
Orofacial growth and development. Mouton & Co., The Hague, pp.
301–330.
- Jungers, W.L., Kaifu, Y., 2011. On dental wear, dental work, and oral health
in the type specimen (LB1) of *Homo floresiensis*. *Am. J. Phys. Anthropol.*
145, 282–289.
- Kaifu, Y., Kasai, K., Townsend, G.C., Richards, L.C., 2003. Tooth wear and
the “design” of the human dentition: a perspective from evolutionary
medicine. *Yearb. Phys. Anthropol.* 46, 47–61.
- Langsjoen, O., 1998. Diseases of the dentition. In: Auderheide,
A.C., Rodríguez-Martín, C. (Eds.), *The Cambridge encyclopedia of
human paleopathology*. Cambridge University Press, Cambridge, pp.
393–412.
- Lebel, S., Trinkaus, E., 2002. Middle Pleistocene human remains from the
Bau de l’Aubesier. *J. Hum. Evol.* 43, 659–685.
- Legge, S.S., 2012. Dentoalveolar abscess variation among three groups
of chimpanzees (*Pan troglodytes schweinfurthii*, *Pan troglodytes
troglodytes*, and *Pan paniscus*). *Int. J. Paleopathol.* 2, 1–9.
- LeResche, L., 1997. Epidemiology of temporomandibular disorders: impli-
cations for the investigation of etiologic factors. *Crit. Rev. Oral Biol.
Med.* 8, 291–305.
- Levers, B.G.H., Darling, A.I., 1983. Continuous eruption of some adult
human teeth of ancient populations. *Arch. Oral Biol.* 28, 401–408.
- Lordkipanidze, D., Vekua, A., Ferring, R., Rightmire, G.P., Agusti, J., Kiladze,
G., Mouskhelishvili, A., Nioradze, M., Ponce de Leon, M.S., Tappen, M.,
Zollikofer, C.P.E., 2005. The earliest toothless hominin skull. *Nature*
434, 717–718.
- Lordkipanidze, D., Jashashvili, T., Vekua, A., de Leon, M.S.P., Zollikofer,
C.P.E., Rightmire, G.P., Pontzer, H., Ferring, R., Oms, O., Tappen, M.,
Bukhsianidze, M., Agusti, J., Kahlke, R., Kiladze, G., Martínez-Navarro,
B., Mouskhelishvili, A., Nioradze, M., Rook, L., 2007. Postcranial
evidence from early *Homo* from Dmanisi, Georgia. *Nature* 449,
305–310.
- Lovell, N.C., 1991. An evolutionary framework for assessing illness and
injury in non-human primates. *Am. J. Phys. Anthropol.* 34, 117–155.
- Lucas, P.W., 2004. Tooth Wear. In: Lucas, P.W. (Ed.), *Dental functional mor-
phology: how teeth work*. Cambridge University Press, Cambridge, pp.
181–201.
- Margvelashvili, A., Zollikofer, C.P.E., Lordkipanidze, D., Peltomäki, T., Ponce
de León, M.S., 2013. Tooth wear and dentoalveolar remodeling are key
factors of morphological variation in the Dmanisi mandibles. *Proc.
Natl. Acad. Sci.* [www.pnas.org/cgi/doi/10.1073/pnas.1316052110].
- Martinón-Torres, M., Bermúdez de Castro, J.M., Gómez-Robles, A., Margve-
lashvili, A., Prado, L., Lordkipanidze, D., Vekua, A., 2008. Dental remains
from Dmanisi (Republic of Georgia): morphological analysis and com-
parative study. *J. Hum. Evol.* 55, 249–273.
- Martinón-Torres, M., Martín-Francés, L., Gracia, A., Olejniczak, A.J., Prado-
Simón, L., Gómez-Robles, A., Lapresa, M., Carbonell, E., Arsuaga, J.L.,
Bermúdez de Castro, J.M., 2011. Early Pleistocene human mandible
from Sima del Elefante (TE) cave site in Sierra de Atapuerca (Spain): a
paleopathological study. *J. Hum. Evol.* 61, 1–11.
- McNeill, C., Mohl, N.D., Rugh, J.D., Tanaka, T.T., 1990. Temporomandibular
disorders: diagnosis, management, education, and research. *J. Am.
Dent. Assoc.* 120, 253–263.
- Milner, G.R., Larsen, C.S., 1991. Teeth as artifacts of human behaviour:
intentional mutilation and accidental modification. In: Kelley, M.A.,
Larsen, C.S. (Eds.), *Advances in dental anthropology*. John Wiley &
Sons, Inc., New York, pp. 357–378.
- Molnar, S., 1971. Human tooth wear, tooth function and cultural variabil-
ity. *Am. J. Phys. Anthropol.* 34, 175–189.
- Morgan, D., Sanz, C., 2006. Chimpanzee feeding ecology and comparisons
with sympatric gorillas in the Goulougo Triangle, Republic of Congo.
In: Hohmann, G., Robbins, M.M., Boesch, C. (Eds.), *Feeding ecology
in apes and other primates: ecological, physiological and behavioural
aspects*. Cambridge University Press, Cambridge, pp. 97–122.
- Murray, G.M., Phanachet, I., Uchida, S., Whittle, T., 2001. The role of the
human lateral pterygoid muscle in the control of horizontal jaw move-
ments. *J. Orofac. Pain* 15, 279–305.
- Natsume, A., Koyasu, K., Oda, S.-i., Nakagaki, H., Hanamura, H., 2006. Pre-
molar and molar rotation in wild Japanese serow populations on
Honsu Island, Japan. *Arch. Oral Biol.* 51, 1040–1047.
- Newman, H.N., Levers, B.G.H., 1979. Tooth eruption and function in an
early Anglo-Saxon population. *J. R. Soc. Med.* 72, 341–350.
- Nimigeon, V.R., Nimigeon, V., Bencze, M.A., Dimcevic-Poesina, V., Cer-
gan, R., Moraru, S., 2009. Alveolar bone dehiscences and fenestrations:
an anatomical study and review. *Rom. J. Morphol. Embryol.* 50,
391–397.
- Ogden, A.R., 2008a. Periapical voids in human jaw bones. In: Smith, M.,
Brickley, M. (Eds.), *Proceedings of the 8th Annual Meeting of the
British Association for Biological Anthropology & Osteoarchaeology:
British Archaeological Reports International Series 1743*. Archaeo-
press, Oxford, pp. 51–56.
- Ogden, A.R., 2008b. Advances in the paleopathology of teeth and jaws. In:
Mays, S., Pinhasi, R. (Eds.), *Advances in human paleopathology*. Wiley,
Chichester, pp. 283–307.
- Patterson, D.K., 1984. A diachronic study of dental paleopathology and
attritional status of prehistoric Ontario Pre-Iroquois and Iroquois popu-
lations. National Museum of Man Mercury Series, Archaeological
Survey of Canada, Paper 122, Ottawa.
- Platzer, W., 2004. Color atlas of human anatomy. *Locomotor System*, 1.
Thieme, Stuttgart, 462 p.
- Pontzer, H., Scott, J.R., Lordkipanidze, D., Ungar, P.S., 2011. Dental
microwear texture analysis and diet in the Dmanisi hominins. *J. Hum.
Evol.* 61, 683–687.

- Primožič, J., Farčnik, F., Ovsenika, M., 2012. Places in the dental arch that show a greater variability in tooth number, shape and position. A prevalence study. *Arch. Oral Biol.* 57, 744–748.
- Rightmire, G.P., Lordkipanidze, D., Vekua, A., 2006. Anatomical descriptions, comparative studies and evolutionary significance of the hominin skulls from Dmanisi, Republic of Georgia. *J. Hum. Evol.* 50, 115–141.
- Rightmire, G.P., Van Arsdale, A.P., Lordkipanidze, D., 2008. Variation in the mandibles from Dmanisi. *Georgia. J. Hum. Evol.* 54, 904–908.
- Rosas, A., Bermúdez de Castro, J.M., 1998. On the taxonomic affinities of the Dmanisi mandible (Georgia). *Am. J. Phys. Anthropol.* 107, 145–162.
- Rupprecht, R.D., Horning, G.M., Nicoll, B.K., Cohen, M.E., 2001. Prevalence of dehiscences and fenestrations in modern American skulls. *J. Periodontol.* 72, 722–729.
- Scott, G.R., Winn, J.R., 2011. Dental chipping: contrasting patterns of microtrauma in Inuit and European populations. *Int. J. Osteoarchaeol.* 21, 723–731.
- Skinner, M.M., Gordon, A.D., Collard, N.J., 2006. Mandibular size and shape variation in the hominins at Dmanisi, Republic of Georgia. *J. Hum. Evol.* 51, 36–49.
- Smith, P., 1977. Regional variation in tooth size and pathology in fossil hominids. *Am. J. Phys. Anthropol.* 47, 459–466.
- Smith, B.H., 1984. Patterns of molar wear in hunter-gatherers and agriculturalists. *Am. J. Phys. Anthropol.* 63, 39–56.
- Smith, N.R., 2011. Interproximal tooth wear: an in vivo pilot study. *University of Iowa, Iowa*, pp. 77.
- Tallgren, A., Solow, B., 1991. Age differences in adult dentoalveolar heights. *Eur. J. Orthod.* 13, 149–156.
- Tappen, N.C., 1985. The dentition of the “old man” of La Chapelle-aux-Saints and inferences concerning Neandertal behavior. *Am. J. Phys. Anthropol.* 67, 43–50.
- Teaford, M.F., Ungar, P.S., 2000. Diet and the evolution of the earliest human ancestors. *Proc. Natl. Acad. Sci. U S A* 97, 13506–13511.
- Ten Cate, A.R., 1998. Physiologic tooth movement: eruption and shedding. In: Ten Cate, A.R. (Ed.), *Oral Histology development, structure and function*. Mosby-Year Book, Inc., Missouri, pp. 289–314.
- Trinkaus, E., 1985. Pathology and the posture of the La Chapelle-aux-Saints Neandertal. *Am. J. Phys. Anthropol.* 67, 19–41.
- Ulhaas, L., Kullmer, O., Chrenk, F., 2007. Tooth wear and diversity in early hominid molars: a case study. In: Bailey, S.E., Hublin, J.-J. (Eds.), *Dental perspectives on human evolution*. Springer, Dordrecht, pp. 369–390.
- Ungar, P.S., 1994. Patterns of ingestive behaviour and anterior Tooth use differences in sympatric anthropoid primates. *Am. J. Phys. Anthropol.* 95, 197–219.
- Ungar, P.S., Grine, F.E., 1991. Incisor size and wear in *Australopithecus africanus* and *Paranthropus robustus*. *J. Hum. Evol.* 20, 313–340.
- Vekua, A., Lordkipanidze, D., Rightmire, G.P., Agusti, J., Ferring, R., Maisuradze, G., Mouskhelishvili, A., Nioradze, M., Ponce de Leon, M., Tappen, M., Tvalchrelidze, M., Zollikofer, C., 2002. A new skull of early *Homo* from Dmanisi, Georgia. *Science* 297, 85–89.
- Wallace, J.A., 1975. Did La Ferrassie I use his teeth as a tool? *Curr. Anthropol.* 16, 393–401.
- Whittaker, D.K., Griffiths, S., Robson, A., Roger-Davies, P., Thomas, G., Molleson, T., 1990. Continuing tooth eruption and alveolar crest height in an eighteenth-century population from Spitafields, East London. *Arch. Oral Biol.* 35, 81–85.
- Wolpoff, M.H., 1999. Hominid features. In: Wolpoff, M.H. (Ed.), *Paleoanthropology*. McGraw-Hill, New York, pp. 110–163.
- Yang, X., 2002. Magnetic Resonance Imaging of the lateral pterygoid muscle in temporomandibular disorders. *University of Oulu, Oulu*, 79 p.