

1
2
3
4
5
6
7
8
9
10
11
12
13
14
15
16
17
18
19
20
21
22
23
24
25
26
27
28
29
30
31
32
33
34
35
36
37
38
39
40
41
42
43
44
45
46
47
48
49
50
51
52
53
54
55
56
57
58
59
60
61
62
63
64
65

Comparison between two surgical techniques for increasing vocal pitch by endoscopic shortening of the vocal folds.

Juan Carlos Casado-Morente^{a*}, Felipe Luis Benjumea-Flores^a, Bárbara Romero-Gómez^b,
María Soledad Angulo-Serrano^a, Carlos O'Connor-Reina^a, Carlos Casado-Alba^c,
Antonio José Galeas-López^a; Francisco Carricondo^b

^a*Otorhinolaryngology Service, Quironsalud Hospital, Av. Severo Ochoa, 20, 29603 Marbella, Málaga, Spain.*

^b*Laboratory of Neurobiology of Hearing (UCM 910915), Dept. of Immunology, Ophthalmology and Otorhinolaryngology, Faculty of Medicine, University Complutense, IdISSC, Pl. Ramón y Cajal, s/n, 28040 Madrid, Spain.*

^c*Faculty of Medicine, University of Navarra, c. Irunlarrea, 1, 31008 Pamplona, Navarra, Spain*

- Juan Carlos Casado-Morente: jccasadam@hotmail.com
- Felipe Luis Benjumea-Flores: fbenju@gmail.com
- Bárbara Romero-Gómez: brgomez@ucm.es
- María Soledad Angulo-Serrano: msole_as@hotmail.com
- Carlos O'Connor-Reina: coconnor@us.es
- Carlos Casado-Alba: carloscasado1@outlook.com
- Antonio José Galeas-López: antoniogaleas@gmail.com
- Francisco Carricondo: fjcarric@ucm.es

***Corresponding author:** Dr. Juan Carlos Casado Morente. Hospital Quirónsalud Marbella. Avda. Severo Ochoa, 22. 29603 Marbella, Málaga, Spain. e-mail: jccasadam@hotmail.com; Telephone: +34 952 774 200

Declarations of interest: none

ABSTRACT

Objective: To compare two surgical techniques, the Wendler glottoplasty (GP) and its modification, the vocal fold shortening, and retrodisplacement of the anterior commissure (VFSRAC) associated with laser assisted voice adjustment (LAVA) cordotomy, used to feminize the voice of transgender women by increasing the fundamental frequency (F_0).

Methods: A retrospective study of 22 trans women (20-62 yrs-old) was carried out. 12 of them were treated with GP and 10 with the VFSRAC+LAVA technique. They were evaluated before surgery and 6 months after surgery and the postoperative speech therapy. Laryngostroboscopy examination, F_0 measurements, Transgender Woman Voice Questionnaire (TWVQ) assessment and the perceptual assessment using a visual analog scale (PA-VAS) were obtained from all patients.

Results: Laryngostroboscopic findings showed normal vocal folds before surgery and a shortening of the vocal folds, due to the anterior glottic synechia, after surgery. Significant increases of F_0 were found in both groups but they were higher in the VFSRAC+LAVA group (47.75Hz in GP group vs 69.70Hz in VFSRAC+LAVA group). TWVQ scores showed a significant decrease in both groups although the difference was greater in the VFSRAC+LAVA group. Similarly, PA-VAS scores lowered significantly in both groups but VFSRAC+LAVA group presented the biggest decreases.

Conclusion: Both surgical techniques produce the shortening of the vocal folds through an endoscopic approach and result in voices with higher vocal pitch. Of the two techniques presented, the VFSRAC+LAVA produces better results although when compared with previous studies it seems that the LAVA technique may not significantly contribute to the postoperative results. So, the VFSRAC technique followed by postoperative speech therapy could be recommended for trans women who wish to feminize their voice.

1
2 **Key words (MeSH):** Feminization, Voice Recognition, Sex Reassignment Surgery,
3
4 Transgender Persons, Glottis, Voice Quality
5
6
7
8
9
10
11
12
13
14
15
16
17
18
19
20
21
22
23
24
25
26
27
28
29
30
31
32
33
34
35
36
37
38
39
40
41
42
43
44
45
46
47
48
49
50
51
52
53
54
55
56
57
58
59
60
61
62
63
64
65

1. INTRODUCTION

1
2 In 2019 the World Health Organization stopped considering transsexuality as an
3 illness and recognized it as a condition [1]. Transsexuality is the result of a lack of
4 coherence between the gender identity of the person and their biological sex from birth.
5
6 This condition can serve as a predisposing element for significant stress, leading in many
7 cases to gender dysphoria, which involves a high cost both for the individual and the
8 society.
9

10
11
12
13
14
15
16
17 Nowadays, the prevalence of this condition is increasing in our society. In Spain,
18 22.1 in 100,000 inhabitants are estimated to have gender dysphoria: 31.2 for trans women
19 and 12.9 for trans men, which makes the ratio of trans women to trans men approximately
20 2.2:1 [2]. The ever increasing acceptance of transgender individuals by society has led to
21 an increase in the need to receive treatments that develop physical and behavioral
22 characteristics in this population that match their gender identity. Likewise, the rising
23 cases in this condition also reflects that it is a relevant issue that must be addressed. Initial
24 treatment consists of psychological, emotional, and hormonal support, although surgical
25 treatments may also be required to achieve the expected result.
26
27
28
29
30
31
32
33
34
35
36
37

38
39 The morphology of the larynx and the voice are secondary sexual characteristics
40 that identify people within a gender. The World Professional Association for Transgender
41 Health (WPATH) considers them as aspects that need to be considered within the
42 assistance of the transsexual person [3]. A deeper pitch of voice, between 80–165 Hz, is
43 identified as a male voice, and conversely a higher tone, between 145-275 Hz, is
44 associated with a female voice [4]. Hormonal treatment can produce a change in their
45 larynx and a voice in trans men without the need of other treatments even though up to
46 20% of transsexual men may have problems with their voice despite hormonal treatment
47
48
49
50
51
52
53
54
55
56
57
58
59
60
61
62
63
64
65

1 experience, it is easy to find trans-women with a feminine appearance but with a
2 masculine voice. In some cases, speech therapy achieves the desired tone and voice
3 characteristics, but if this is not enough, trans women undergo surgical treatment to alter
4 their voice quality.
5
6
7
8

9 Voice feminization is a part of the complicated and exhaustive process of
10 transition for trans women. It should not be considered only as an increase in vocal pitch.
11 Gender differences in physical, neurophysiological, and acoustic characteristics of the
12 voice must also be considered [3] which makes vocal therapy (surgical or not) very
13 important. In general, this process depends on the fundamental frequency of the voice
14 (F_0) (determined by vocal fold length and mass), the vowel formant frequencies and its
15 relationship with the vocal resonance (determined by the shape of the vocal tract), and
16 the phonatory pattern [6]. This process of change can be divided into surgical treatment
17 and non-surgical treatment that would include vocal feminization therapy to modify oral
18 and pharyngeal resonance, as well as gesture and vocal behavior.
19
20
21
22
23
24
25
26
27
28
29
30
31
32
33

34 Different surgical techniques have been developed sharing a same purpose, the
35 increase of F_0 to obtain a voice that can be identified as feminine. All techniques are based
36 on three principles: shortening, increasing tension and/or reducing the mass of the vocal
37 folds [7]. The two most popular techniques to date are the cricothyroid approach (CTA)
38 [8] and the Wendler glottoplasty (GP) that creates a new anterior commissure [9]. Other
39 techniques described are laser assisted voice adjustment to laser cordotomy [10], an
40 anterior commissure advancement [11] or feminization laryngoplasty [12]. Modifications
41 of both techniques, and combinations of several of them, have been used to keep balanced
42 results over time.
43
44
45
46
47
48
49
50
51
52
53
54

55 With this aim in mind, our group has worked on the development of a new
56 approach that consists of the combination of two techniques: the modification of the GP
57
58
59
60
61
62
63
64
65

1 called vocal fold shortening and retrodisplacement of the anterior commissure (VFSRAC)
2 [13] associated with laser assisted voice adjustment (LAVA) cordotomy. The purpose of
3 this study is to present the results obtained with this technique comparing them with the
4 Wendler GP technique.
5
6
7
8
9

10 11 12 **2. MATERIALS AND METHODS**

13
14
15 A retrospective study of the two surgical treatments was carried out. This study
16 was approved by the hospital ethics committee and was in accordance with the 1964
17 Helsinki declaration and its later amendments or comparable ethical standards. Patients,
18 after conversation with the surgeon, underwent consecutively the surgical treatment
19 decided taking in mind the surgeon criteria and the patient opinion, between April 2017
20 and January 2020. A total of 22 patients, with an age range between 20-62 yrs-old
21 (mean=36.6), were included in the study and divided into 2 groups, depending on the
22 applied treatment:
23
24
25
26
27
28
29
30
31
32

- 33
34 • **Group GP:** 12 patients aged between 25-62 yrs-old (mean 38.25, SD 12.18) were
35 treated with the Wendler GP technique.
36
37
- 38 • **Group VFSRAC+LAVA:** 10 patients aged between 20-47 yrs-old (mean 34.70,
39 SD 9.45) were treated with VFSRAC and LAVA techniques as previously
40 described [14,15].
41
42
43
44
45
46
47
48

49 Both groups were operated on by the same surgeon under general anesthesia. The
50 larynx was exposed with adequate vision of the anterior commissure, using direct
51 laryngoscopy.
52
53
54
55

56 In group GP, the new anterior commissure was formed by a de-epithelialization
57 of the upper and lower surfaces and the free edge of the anterior part of the vocal folds
58
59
60
61
62
63
64
65

1 (the vocal fold is divided into three thirds, and the suture is performed in the first third
2 (anterior third of the vocal fold), as described by Wendler [9]) by using cold instruments
3 followed by the suture of the anterior part of both folds creating a V-shape hiatus, with 4-
4
5
6
7 0 vicryl sutures, that could be reinforced by fibrin or biological glue.
8

9
10 In group VF SRAC+LAVA, the de-epithelialization of the anterior third of both
11 vocal folds, the anterior commissure, and the portion in contact with the subglottis at the
12 cricothyroid level (approximately 1 cm) was performed, also with the use of cold
13 instruments. The excision includes the lamina propria and the submucosal glands
14 extending up to the cricothyroid membrane. The anterior commissure was displaced from
15 its original position by two permanent stitches (5-0 double-needle prolene suture); the
16 first suture is placed on the thyro-arytenoid muscle, including the subglottic portion, and
17 the second and posterior suture that lies exclusively on the vocal muscle, simplifying the
18 surgical technique by shortening the surgical time. Once the new anterior commissure
19 was made, the upper surface of both vocal folds was vaporized by using diode laser with
20 a power of 5W or less, 1-2mm from the free edge of the same, extending from the vocal
21 process towards the anterior commissure, as close as possible, without damaging it. After
22 surgery and in both groups, patients had to be in complete vocal rest for the 15 days
23 following surgical treatment to limit the tension of the vocal folds and prevent dehiscence
24 of the suture.
25
26
27
28
29
30
31
32
33
34
35
36
37
38
39
40
41
42
43
44

45
46 All patients were evaluated prior to surgery and received postoperative speech
47 therapy, either in a face-to-face consultation or telematics, with a detailed follow-up at 1,
48 3 and 6 months after surgery. To be considered for the study, patients should have
49 received at least 10 speech therapy sessions. At 6 months after surgery, next data were
50 obtained from patients for present study:
51
52
53
54
55
56
57
58
59
60
61
62
63
64
65

- 1 • Laryngostroboscopy [Atmos Endo-Stroboscope L 250 W; continuous light, slow
2 motion of 0.5 up to 2 Hz; freeze image 0° - 400°; phase shifting; pilot flash for
3 approximately 10 s; adjustable frequency from 100 to 400 Hz (+/- 10%)].
4
- 5 • Fundamental frequency (F_0 (Hz)) obtained with the software for scientific analysis
6 of speech PRAAT (<http://www.fon.hum.uva.nl/praat/>).
7
- 8 • The subjective assessment of the voice was determined using the “Trans Woman
9 Voice Questionnaire” (TWVQ) that consists of 30 questions, with 0 as minimum
10 and 120 as maximum score attainable. A high score on the TWVQ indicates a
11 voice perception not as feminine as desired with consequences in the quality of
12 life [16].
13
- 14 • Perceptual assessment using a visual analog scale (PA-VAS), from 1 to 5, being
15 1 a very feminine voice, 2 a somewhat feminine voice, 3 a gender-neutral voice,
16 4 a somewhat masculine voice and 5 a very masculine voice. The patient must
17 read the first fragment of a famously known narrative Spanish text, «Platero y yo»
18 by the Spanish Nobel Prize of Literature Juan Ramón Jiménez (“Platero is small,
19 hairy, soft...”). This text has a wide phonetic variability and is frequently used in
20 otolaryngology practice and speech therapy consultation for perceptual
21 assessment of the voice. Expert reviewers, two ENT specialists with more than 15
22 years of experience in the field of laryngology and a speech therapist specialized
23 in feminization of the voice, were instructed to upload the recordings into the
24 VAS. They were not blinded to the patient surgery.
25
26
27
28
29
30
31
32
33
34
35
36
37
38
39
40
41
42
43
44
45
46
47
48
49
50

51 Mean and standard deviations of the considered variables were calculated. The
52 statistical analysis was performed using ANOVA and the differences were statistically
53 interpreted at a 5% (*), 1% (**), and 0.1% (***) confidence level.
54
55
56
57
58
59
60
61
62
63
64
65

3. RESULTS

The preoperative laryngostroboscopy presented larynx with normal male characteristics, without pathology, except for some cases with interarytenoid pachydermia. The appearance of the vocal folds was normal, with adequate glottic closure and a symmetrical vibration wave of the vocal folds. Comparing video laryngeal stroboscopy images obtained before surgery with postoperative images obtained 3 months after surgery, an anterior synechia was observed, with a shortening in the length of the glottic space, although it seemed more pronounced in the case of the VFSRAC+LAVA group (Fig. 1).

Some complications derived from the surgery were observed. In the GP group, 1 case of anterior granuloma (Fig. 2) and 1 case of dehiscence of the suture, while in the VFSRAC+LAVA group, there were 5 cases of anterior granuloma and 3 cases of persistence of the suture. However, these complications were not clinically relevant in the result of the voice as none of the patients' showed symptoms.

The F_0 measured after surgical treatment (Fig. 3 and Table 1) increased significantly in both groups, although only in the VFSRAC+LAVA group an increase in F_0 above 160Hz was observed in all cases. The GP group showed an increase of 47.75Hz (CI 31.33-64.16) after surgery (129.08Hz to 176.83Hz). VFSRAC+LAVA group showed a higher increase of the F_0 after surgery of 69.7Hz (IC 53.02-86.37) (131.90 to 201.6Hz). There was a statistically significant difference of 21.95Hz greater in the VFSRAC+LAVA group when compared postsurgical F_0 with the GP group.

The voice perception also changed in both groups (Fig. 3 and Table 1). So, TWVQ score of the GP group decreased from 83.83 to 54.83 while in VFSRAC+LAVA group, TWVQ decreased from 94.7 to 35.6. Both are statistically significant improvements, 29

1 points in the group GP compared to 54.83 points in the VFSRAC+LAVA group (25.83
2 points between both groups (CI 9.73-41.93, $p < 0.05$)).
3

4 A significant improvement was also observed in both treatment groups in the PA-
5 VAS score (Fig. 3 and Table 1). For the GP group, PA-VAS changed from 4.5, somewhat
6 masculine voice, to 2.67, somewhat female voice (difference=1.83), while the
7 VFSRAC+LAVA group showed a decrease from 4.3 points, somewhat masculine voice,
8 to 1.3, female voice (difference=3). Comparing both groups, a significant improvement
9 in the PA-VAS score was observed in the VFSRAC+LAVA group by 1.17 points (IC
10 0.55-1.79).
11
12
13
14
15
16
17
18
19
20
21
22
23

24 **4. DISCUSSION**

25 The surgical treatment of voice feminization consists of the application of
26 different surgical techniques aimed to increase the F_0 . These surgical procedures should
27 attempt to achieve these fundamental principles: increasing tension, thinning mass and
28 shortening the length of the vocal folds. So, after surgery, the vocal folds should be
29 shorter, thinner and tighter [7]. For this reason, surgical techniques can be divided into
30 three categories depending on whether they modify one, two or three of these fundamental
31 principles discussed above [17]. They can be done using techniques with external or
32 endoscopic approach [18].
33
34
35
36
37
38
39
40
41
42
43
44

45 Different systematic reviews and meta-analyzes have been carried out on the
46 efficacy of each of these techniques for voice feminization. Some studies concluded that
47 there is no scientific evidence of which surgical technique is better for vocal feminization
48 in transgender women [19,20], while others concluded that the greatest increase of the F_0
49 was observed after endoscopic shortening techniques [21].
50
51
52
53
54
55
56
57
58
59
60
61
62
63
64
65

1
2
3
4
5
6
7
8
9
10
11
12
13
14
15
16
17
18
19
20
21
22
23
24
25
26
27
28
29
30
31
32
33
34
35
36
37
38
39
40
41
42
43
44
45
46
47
48
49
50
51
52
53
54
55
56
57
58
59
60
61
62
63
64
65

In the present study, two endoscopic surgical techniques that raise the pitch shortening the vocal folds are compared. The GP technique consists of the modification of the "length" factor to increase the vocal pitch by shortening the length of the vocal folds. First described by Wendler [9] it has had later modifications that have been added [22]. Some authors describe the process over the anterior synechia by approaching both de-epithelialized areas from the anterior part of the vocal folds by means of an infiltration of hydroxyapatite (gel format) in the thyroarytenoid muscle instead of suturing the epithelium of the vocal folds [23]. Other authors, once the anterior glottic suture has been performed, induce muscle rest for several weeks by injecting 2.5 IU of botulinum toxin into both vocal folds [20]. With this surgical technique, a steady over time F_0 significant increase at 6 weeks between 44 and 85 Hz (about 9 semitones) was obtained. Postoperative F_0 is maintained in follow-ups of up to 39, 45 or 48 months [24-27]. The anterior synechia remains stable for at least four years after surgery [23]. This is the reason why it is probably the most widely used technique to increase vocal pitch in this population.

Previous technique was compared with VFSTRAC in this study [13]. This technique also consists of the creation of a glottic anterior synechia but it achieves significant physiological changes, so both "length" and "tension" factors are modified, resulting on shorter and more tense vocal folds. In the study by Kim et al. [13], from a cohort of 362 patients (of whom 313 were transgender women), a mean postoperative F_0 of 187 ± 20.8 Hz was obtained with an increase of F_0 73.6 Hz [13].

So, in present study, the GP group correspond to the first patients performed with the original technique described by Wendler. As the technique developed and inspired by Kim's technique that produced a further increase in the F_0 carrying out glottoplasty by shortening the length of the vocal cord by retrodisplacing the anterior commissure, and

1 the LAVA technique, described by Orloff, that affects another aspect in the production of
2 the F_0 , which is the lower mass of the vocal cord obtained after the laser cordotomy, we
3
4 decided to combine both techniques.
5
6

7 With the hypothetical objective of augmenting F_0 even more with the LAVA
8
9 technique [10], that increases vocal pitch by thinning the vocal folds, the method was
10
11 combined with the VFSRAC technique, so that a reduction of the mass and density of the
12
13 vocal folds was possible. However, from a practical-clinical point of view, the use of the
14
15 LAVA technique by itself is of limited utility since the mean increase in F_0 is 26Hz. As
16
17 it is a technique in which the increase in the F_0 is lesser than with other techniques to
18
19 achieve a feminine range, its exclusive use without combination with other techniques
20
21 may be limited to trans women who have a voice with a F_0 within the considered
22
23 ambiguous range (F_0 between 140-160dB), since below this range we assume that the
24
25 exclusive use of this surgical technique will provide an insufficient result.
26
27
28
29
30

31 Laryngoscopy images obtained after both surgical techniques are similar: larynx
32
33 with shortened vocal folds and with higher tension are observed, although the
34
35 VFSRAC+LAVA group presents thinner vocal folds with less mass when these images
36
37 were compared with video laryngeal stroboscopy images obtained before surgery (Fig.
38
39
40
41 1).
42

43 Regarding F_0 (Fig. 3 and Table 1), a postoperative F_0 mean of 176.83Hz was
44
45 obtained in the GP group, with an increase of 47.75Hz that coincides with other similar
46
47 studies [14,15,24,26,27]. The VFSRAC+LAVA group showed a postoperative F_0 mean
48
49 of 201.6Hz, with an increase of 69.7Hz. In the original VFSRAC technique, the described
50
51 F_0 increase was 73.6Hz, slightly higher than the obtained in the present study, when the
52
53 LAVA procedure was added to the original. However, this increase of F_0 is only of
54
55
56
57
58 50.8Hz in patients above 50 years-old, which is something to consider in the case of
59
60
61
62
63
64
65

1 proceeding to voice feminization in older patients. The VFSRAC technique produces
2 significant changes in the larynx, since it modifies the three fundamental factors (tension,
3 length, and mass) of the vocal folds. These changes are achieved by using permanent
4 suture material and suturing the thyroarytenoid muscle to the internal perichondrium of
5 the subglottic portion of the thyroid cartilage. So, the vocal folds are made shorter, tighter,
6 and thinner with a simple surgical procedure. Based on the present results and when
7 compared with a previous study by Kim [13,17], it does not seem that the addition of the
8 LAVA technique to GP provides an extra benefit in the final result in terms of raising the
9 vocal pitch of our patients, although further studies would be necessary before stating
10 such conclusion. It would be interesting to be able to predict the resulting postoperative
11 F_0 based on the glottic synechia created and the final length of the vocal folds [28].

26 About the perception that patients have of their own voice (Fig. 3 and Table 1), a
27 significant improvement in the TWVQ score was observed in both groups, 29 points in
28 GT group compared with 54.83 points in the VFSRAC group and a significant difference
29 of 25.83 points between both groups (CI 9.73-41.93). So, the subjective assessment of the
30 voice improved significantly in the VFSRAC+LAVA group. This coincides with other
31 studies [29] and goes along with the improvement in voice self-perception related to
32 quality of life in the case of Kim's original technique, measured by the Voice Handicap
33 Index (VHI): the result was satisfactory in 82.5% [13].

46 Regarding the perceptual assessment by expert examiners using a VAS, favorable
47 results have been published in other studies [4,30]. In the present study, an increase and
48 improvement of the perception of voice femininity is obtained in both groups after surgery
49 (2.67 points in the group GP and 1.3 in the VFSRAC+LAVA group). Comparing both
50 groups, an improvement in the PA-VAS is observed in the VFSRAC+LAVA group by

1.17 points, which implies a change from a somewhat feminine voice to a feminine voice (CI 0.55-1.79).

In present study, as in most published studies, the results are short-term. More studies are needed to show long-term results (over 6 months) that probe the effectiveness of treatment over time. In any case, results in present study are reproducible in the short term and with statistical significance (<0.05).

In conclusion, both GP and VFSRAC procedures consist of the shortening of the vocal folds by endoscopic approach. In both cases, postoperative complementary vocal therapy is used. From the analysis of our results, which are statistically significant, and are also in accordance with those published in other studies with the same characteristics, both procedures are useful to achieve a more feminine voice, considering not only the numerical value of the F_0 , but also the self-perception by the patient and the perceptual assessment by expert examiners.

In general, better results were achieved with the VFSRAC+LAVA technique than with Wendler's GP. Also, the LAVA technique associated with VFSRAC does not provide extra benefit to the final results when comparing our results with those obtained by other authors [13,17], although more studies would be needed to reach that final conclusion. As in any other surgical procedure, a learning curve is required with earlier surgeries resulting in tedious and long to perform. However, the VFSRAC technique is somewhat more complex to perform since the suture of the anterior subglottic point will involve greater dexterity and ability. The use of a double needle suture (which allows the stitching from the subglottis to the glottis) makes this surgical technique easier and shortens the surgery time considerably.

Present study is a retrospective study of our daily clinical experience in the past years in which a small sample size in each experimental group was included following

1 the criteria of the surgeon and patient desires and concerns. Nonetheless, data obtained
2 offered strong evidence with clear and statistical significant differences in the proposed
3 comparisons of the study which conclusions are in agreement with other related studies.
4 One of the weak points of present study is that, due to ethical problems, it is difficult to
5 carry out a randomized or blind study in these patients, since the considered best available
6 technique should be applied for each patient. This is a retrospective study, to compare the
7 initial surgical technique we used with the one we currently use, being both techniques
8 already described and well known. After surgery, patients of both experimental groups
9 received the same quantity and type of speech therapy by the same speech therapist. The
10 novelty in this study is this later technique that is the combination of two techniques,
11 VFSRAC and LAVA, that, although they have been described, there are no publications
12 in the revised bibliography that combined this both techniques.
13
14
15
16
17
18
19
20
21
22
23
24
25
26
27
28

29 Future studies, with different designs, prospective, randomized, etc., could
30 support our conclusions and delve into the possibility of predicting the resulting
31 postoperative F_0 as a function of the length of the glottic anterior synechia and, therefore,
32 of the length of the vocal folds.
33
34
35
36
37
38
39
40

41 **5. ACKNOWLEDGMENTS**

42 Authors are grateful to Teresa López Soto, PhD Computational Linguistics, Associate
43 Professor of English Philology of the University of Sevilla (Spain), for language revision
44 of the manuscript. Also, we want to thank all the trans women who have trusted us.
45
46
47
48
49
50
51
52
53
54
55
56
57
58
59
60
61
62
63
64
65

REFERENCES

- 1
2
3
4
5
6
7
8
9
10
11
12
13
14
15
16
17
18
19
20
21
22
23
24
25
26
27
28
29
30
31
32
33
34
35
36
37
38
39
40
41
42
43
44
45
46
47
48
49
50
51
52
53
54
55
56
57
58
59
60
61
62
63
64
65
1. E. Coleman, W. Bockting, M. Botzer, P. Cohen-Kettenis, G. DeCuypere, J. Feldman, L. Fraser, J. Green, G. Knudson, W. J. Meyer, S. Monstrey, R.K. Adler, G.R. Brown, A.H. Devor, R. Ehrbar, R. Ettner, E. Eyler, R. Garofalo, D.H. Karasic, A.I. Lev, G. Mayer, H. Meyer-Bahlburg, B.P. Hall, F. Pfaefflin, K. Rachlin, B. Robinson, L.S. Schechter, V. Tangpricha, M. van Trotsenburg, A. Vitale, S. Winter, S. Whittle, K.R. Wylie, K. Zucker. Standards of Care for the Health of Transsexual, Transgender, and Gender-Nonconforming People, Version 7. *Int J Transgenderism*. 13(2012), 165-232. <https://doi.org/10.1080/15532739.2011.700873>.
2. A. Becerra-Fernández, J.M. Rodríguez-Molina, N. Asenjo-Araque, M.J. Lucio-Pérez, M. Cuchí-Alfaro, E. García-Camba, G. Pérez-López, M. Menacho-Román, M.C. Berrocal-Sertucha, D. Ly-Pen, M.V. Aguilar-Vilas. Prevalence, Incidence, and Sex Ratio of Transsexualism in the Autonomous Region of Madrid (Spain) According to Healthcare Demand. *Arch Sex Behav*. 46(2017):1307-1312. <https://doi.org/10.1007/s10508-017-0955-z>.
3. S. Davies, V.G. Papp, C. Antoni. Voice and Communication Change for Gender Nonconforming Individuals: Giving Voice to the Person Inside. *Int J Transgenderism*. 16(2015):117-159. <https://doi.org/10.1080/15532739.2015.1075931>.
4. J. Meister, H. Kühn, W. Shehata-Dieler, R. Hagen, N. Kleinsasser. Perceptual analysis of the male-to-female transgender voice after glottoplasty-the telephone test. *Laryngoscope*. 127(2017):875-881. <https://doi.org/10.1002/lary.26110>.
5. U. Nygren, A. Nordenskjöld, S. Arver, M. Södersten. Effects on Voice Fundamental Frequency and Satisfaction with Voice in Trans Men during Testosterone Treatment-

A Longitudinal Study. *J Voice*. 30(2016):766.e23-766.e34.

<https://doi.org/10.1016/j.jvoice.2015.10.016>.

6. S.J.K. Gallena, B. Stickels, E. Stickels. Gender Perception After Raising Vowel Fundamental and Formant Frequencies: Considerations for Oral Resonance Research. *J Voice*. 32(2018):592-601. <https://doi.org/10.1016/j.jvoice.2017.06.023>.
7. I.R. Titze, A. Palaparthi, T. Mau. Vocal Tradeoffs in Anterior Glottoplasty for Voice Feminization. *Laryngoscope*. 131(2021):1081-1087. <https://doi.org/10.1002/lary.28940>
8. N. Isshiki, T. Taira, M. Tanabe. Surgical alteration of the vocal pitch. *J Otolaryngol*. 12(1983):335-40.
9. J. Wendler. Vocal pitch elevation after transsexualism male to female. In: *Proceedings of the Union of the European Phoniaticians; Salsomaggiore, Italy*. 1990.
10. L.A. Orloff, A.P. Mann, J.F. Damrose, S.N. Goldman. Laser-assisted voice adjustment (LAVA) in transsexuals. *Laryngoscope*. 116(2006):655-60. <https://doi.org/10.1097/01.mlg.0000205198.65797.59>
11. D. Chung, D.H. Tsuji, L.U. Sennes, R. Imamura. Upper displacement of the anterior commissure: experimental study of a new phonosurgical approach to raising vocal pitch. *Ann Otol Rhinol Laryngol*. 116(2007):462-70. <https://doi.org/10.1177/000348940711600612>
12. J.P. Thomas, C. Macmillan. Feminization laryngoplasty: assessment of surgical pitch elevation. *Eur Arch Otorhinolaryngol*. 270(2013):2695-700. <https://doi.org/10.1007/s00405-013-2511-3>

- 1
2
3
4
5
6
7
8
9
10
11
12
13
14
15
16
17
18
19
20
21
22
23
24
25
26
27
28
29
30
31
32
33
34
35
36
37
38
39
40
41
42
43
44
45
46
47
48
49
50
51
52
53
54
55
56
57
58
59
60
61
62
63
64
65
13. H.T. Kim. A New Conceptual Approach for Voice Feminization: 12 Years of Experience. *Laryngoscope*. 127(2017):1102-1108.
<https://doi.org/10.1002/lary.26127>
 14. J.C. Casado, C. O'Connor, M.S. Angulo, J.A. Adrián. Wendler glottoplasty and voice-therapy in male-to-female transsexuals: results in pre- and post-surgery assessment. *Acta Otorrinolaringol Esp*. 67(2016):83-92.
<https://doi.org/10.1016/j.otorri.2015.02.003>
 15. J.C. Casado, M.J. Rodríguez-Parra, J.A. Adrián. Voice feminization in male-to-female transgendered clients after Wendler's glottoplasty with vs. without voice therapy support. *Eur Arch Otorhinolaryngol*. 274(2017):2049-2058.
<https://doi.org/10.1007/s00405-016-4420-8>
 16. J.C. Casado-Morente, E. Mora Rivas, C. O'Connor Reina, S. Angulo Serrano, E. Díaz-Fresno, I. Sandoval-Menéndez, A. Becerra, M.J. Lucio, F Núñez-Batalla. Development and validation of the Spanish abbreviated version of the Transsexual Voice Questionnaire for Male-to-Female Transsexuals. *Acta Otorrinolaringol Esp*. 72(2021):21-26. <https://doi.org/10.1016/j.otorri.2020.01.003>.
 17. H.T. Kim. Vocal Feminization for Transgender Women: Current Strategies and Patient Perspectives. *Int J Gen Med*. 13(2020):43-52.
<https://doi.org/10.2147/IJGM.S205102>.
 18. I.T. Nolan, S.D. Morrison, O. Arowojolu, C.S. Crowe, J.P. Massie, R.K. Adler, S.R. Chaiet, D.O. Francis. The Role of Voice Therapy and Phonosurgery in Transgender Vocal Feminization. *J Craniofac Surg*. 30(2019):1368-1375.
<https://doi.org/10.1097/SCS.00000000000005132>.
 19. K. Schwarz, A.M.V. Fontanari, M.A. Schneider, B.M. Borba Soll, D.C. da Silva, P.M. Spritzer, M.E. Kazumi Yamaguti Dorfman, G. Kuhl, A.B. Costa, C.A. Cielo,

- 1
2
3
4
5
6
7
8
9
10
11
12
13
14
15
16
17
18
19
20
21
22
23
24
25
26
27
28
29
30
31
32
33
34
35
36
37
38
39
40
41
42
43
44
45
46
47
48
49
50
51
52
53
54
55
56
57
58
59
60
61
62
63
64
65
- A. P. Villas Bôas, M. Lobato. Laryngeal surgical treatment in transgender women: A systematic review and meta-analysis. *Laryngoscope*. 127(2017):2596-2603. <https://doi.org/10.1002/lary.26692>
20. S. Van Damme, M. Cosyns, S. Deman, Z. Van den Eede, J. Van Borsel. The Effectiveness of Pitch-raising Surgery in Male-to-Female Transsexuals: A Systematic Review. *J Voice*. 31(2017):244.e1-244.e5. <https://doi.org/10.1016/j.jvoice.2016.04.002>
21. T.E. Song, N. Jiang. Transgender Phonosurgery: A Systematic Review and Meta-analysis. *Otolaryngol Head Neck Surg*. 156(2017):803-808. <https://doi.org/10.1177/0194599817697050>
22. A. Geneid, H. Rihkanen, T.J. Kinnari. Long-term outcome of endoscopic shortening and stiffening of the vocal folds to raise the pitch. *Eur Arch Otorhinolaryngol*. 272(2015):3751-6. <https://doi.org/10.1007/s00405-015-3721-7>.
23. J.A. Anderson. Pitch elevation in transgendered patients: anterior glottic web formation assisted by temporary injection augmentation. *J Voice*. 28(2014):816-21.
24. N.S. Mastronikolis, M. Remacle, M. Biagini, D. Kiagiadaki, G. Lawson. Wendler glottoplasty: an effective pitch raising surgery in male-to-female transsexuals. *J Voice*. 27(2013):516-22. <https://doi.org/10.1016/j.jvoice.2013.04.004>.
25. M. Gross. Pitch-raising surgery in male-to-female transsexuals. *J Voice*. 13(1999):246-50. [https://doi.org/10.1016/s0892-1997\(99\)80028-9](https://doi.org/10.1016/s0892-1997(99)80028-9).
26. T.G. Pinheiro, C.C. Ishikawa, R. Imamura, R. Frizzarini, A.N. Montagnoli, D.H. Tsuji. Fundamental Frequency in Excised Human Larynges after Anterior Glottic Web Formation of Various Extents. *Otolaryngol Head Neck Surg*. 160(2019):672-678. <https://doi.org/10.1177/0194599818813007>.

- 1
2
3
4
5
6
7
8
9
10
11
12
13
14
15
16
17
18
19
20
21
22
23
24
25
26
27
28
29
30
31
32
33
34
35
36
37
38
39
40
41
42
43
44
45
46
47
48
49
50
51
52
53
54
55
56
57
58
59
60
61
62
63
64
65
27. E. Mora, I. Cobeta, A. Becerra, M.J. Lucio. Comparison of cricothyroid approximation and glottoplasty for surgical voice feminization in male-to-female transsexuals. *Laryngoscope*. 128(2018):2101-2109. <https://doi.org/10.1002/lary.27172>.
28. M.L. Rohlfing, J.E. Kuperstock, D. Friedman, J.H. Spiegel. An ex vivo porcine model of the anterior glottoplasty for voice feminization surgery. *Laryngoscope*. 130(2020):E206-E212. <https://doi.org/10.1002/lary.28204>.
29. G. Dacakis, J. Oates, J. Douglas Associations between the Transsexual Voice Questionnaire (TVQMtF) and self-report of voice femininity and acoustic voice measures. *Int J Lang Commun Disord*. 52(2017):831-838. <https://doi.org/10.1111/1460-6984.12319>.
30. K.L. Dahl, L.A. Mahler. Acoustic Features of Transfeminine Voices and Perceptions of Voice Femininity. *J Voice*. 34(2020):961.e19-961.e26. <https://doi.org/10.1016/j.jvoice.2019.05.012>.

TABLE WITH CAPTION

Table 1

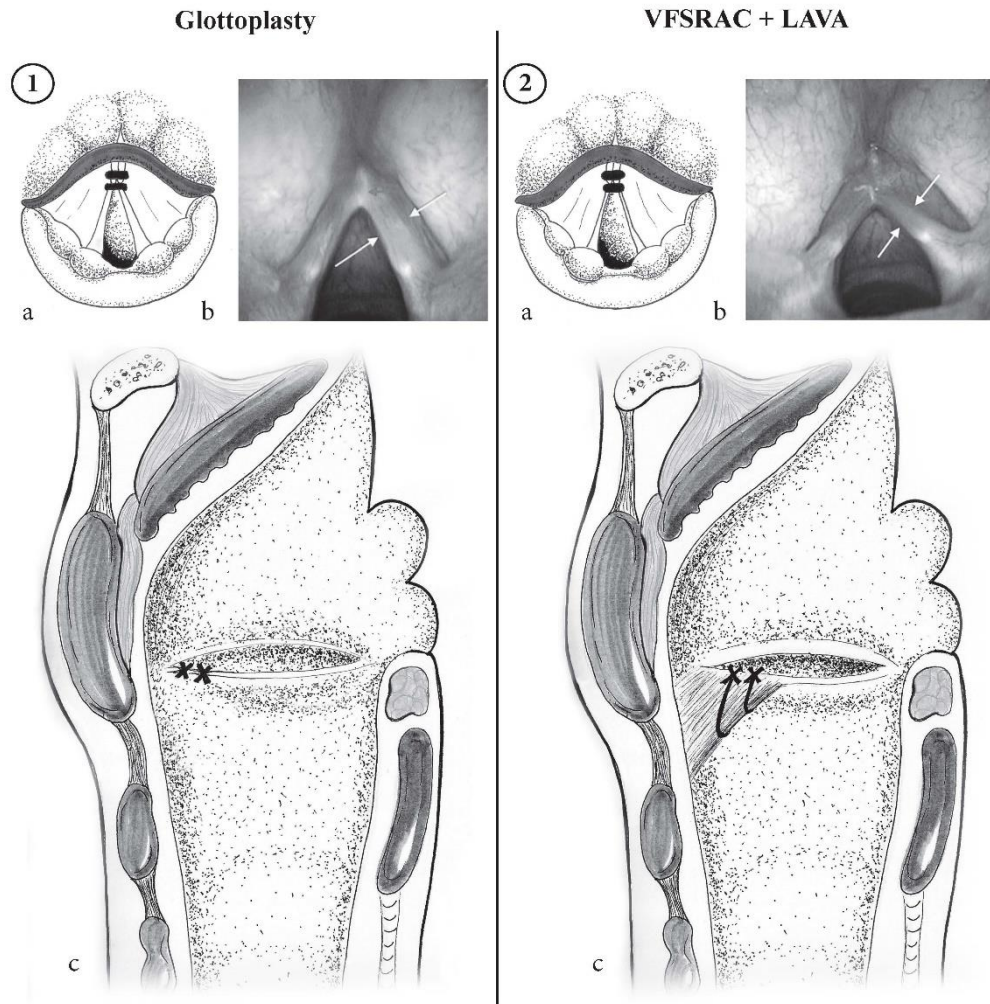
a) GP	pre	post	Δ pre vs post (CI)	p value
F0	129.08 (SD 13.7)	176.83 (SD 20,57)	+47.75(31.33-64.16)	< 0.001
TWVQ	83.83 (SD 17.52)	54.83 (SD 19)	-29(11.83-46.17)	< 0.001
VAS	4.50 (SD 0.52)	2.67 (SD 0.65)	-1.83(1.27-2.38)	< 0.001

b) VFSRAC+LAVA	pre	post	Δ pre vs post (CI)	p value
F0	131.90 (SD 13.63)	201.60 (SD 21.08)	+69.7 (53.02-86.37)	< 0.001
TWVQ	94.70 (SD 14.75)	35.6 (SD 6.6)	-59.1 (69.84-48.36)	< 0.001
VAS	4.30 (SD 0.67)	1.30 (SD 0.48)	-3 (3.55-2.45)	< 0.001

c)	GP	VFSRAC+LAVA	Δ GP vs VFSRAC+LAVA (CI)	p value
F0 pre vs post	47.75 (SD 25.63)	69.70 (SD 16.71)	+21.95 (2.24-41.66)	0.0308
TWVQ pre vs post	29 (SD 17.19)	54.83 (SD 19)	+25.83 (9.73-41.93)	0.0032
VAS pre vs post	1.83 (SD 0.72)	3 (SD 0.67)	+1.17 (0.55-1.79)	0.0009

Table 1: GT and VFSRAC+LAVA pre- and post-treatment F₀, TWVQ and PA-VAS data and p-values of the statistical comparisons. Means and standard deviations for the GP group (a) and for the VFSRAC+LAVA group (b) showing the difference pre- vs. post-surgery in F₀, TWVQ and VAS. c) F₀, TWVQ and PA-VAS pre- and post-surgery in GP and VFSRAC+LAVA groups, comparing the results obtained in both groups.

Figure 1



1
2
3
4
5
6
7
8
9
10
11
12
13
14
15
16
17
18
19
20
21
22
23
24
25
26
27
28
29
30
31
32
33
34
35
36
37
38
39
40
41
42
43
44
45
46
47
48
49
50
51
52
53
54
55
56
57
58
59
60
61
62
63
64
65

Figure 2

1
2
3
4
5
6
7
8
9
10
11
12
13
14
15
16
17
18
19
20
21
22
23
24
25
26
27
28
29
30
31
32
33
34
35
36
37
38
39
40
41
42
43
44
45
46
47
48
49
50
51
52
53
54
55
56
57
58
59
60
61
62
63
64
65

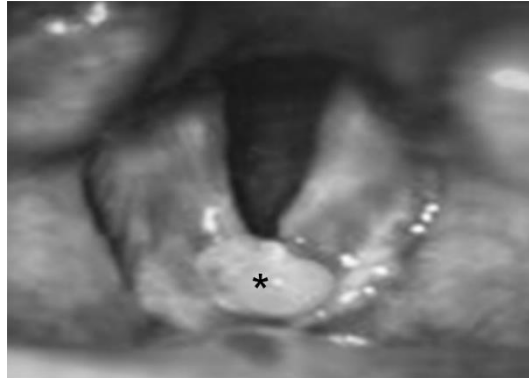
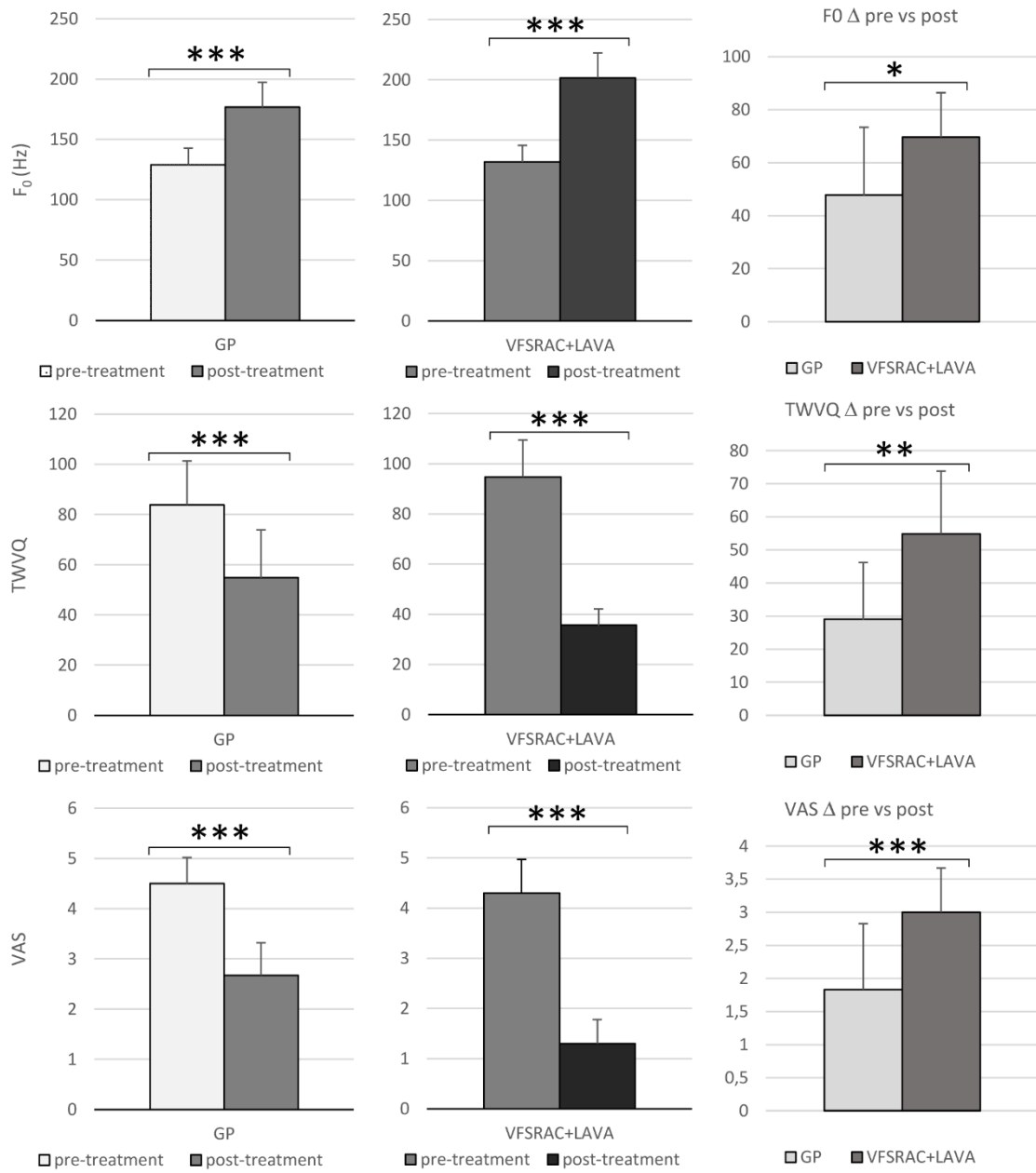


Figure 3



1
2
3
4
5
6
7
8
9
10
11
12
13
14
15
16
17
18
19
20
21
22
23
24
25
26
27
28
29
30
31
32
33
34
35
36
37
38
39
40
41
42
43
44
45
46
47
48
49
50
51
52
53
54
55
56
57
58
59
60
61
62
63
64
65

FIGURE CAPTIONS

1
2
3 **Figure 1:** Comparison of both surgical techniques: GT vs VFSRAC+LAVA. a) Schemes
4 of the glottis seen from above showing the location of the stitches (black arrows) in the
5 anterior third of the vocal folds in both techniques; b) Laryngoscopic images of the glottis
6 showing the post-operative anterior glottic synechia after both treatments: GT leave the
7 vocal fold shorter (1b, white arrows) while after VFSRAC+LAVA the vocal folds are
8 shorter and thinner (2b, white arrows). c) Schemes of sagittal views of the larynx showing
9 the location of the stitches (black X-shaped crosses) in both surgical techniques: In GT,
10 both stitches include only the thyroarytenoid muscle (1c) while in VFSRAC+LAVA the
11 anterior stitch (black heavy arrow) includes both the thyroarytenoid muscle and 1cm of
12 the subglottic portion below it (black asterisk) (2c).

13
14
15
16
17
18
19 **Figure 2:** A complication derived from the surgery. Anterior granuloma (asterisk)
20 observed in the glottis of some patients after the surgery.

21
22
23
24
25
26
27
28
29 **Figure 3:** Histograms showing the values of F_0 , TWVQ and PA-VAS, before and after
30 both GT and VFSRAC+LAVA surgery techniques. Both techniques showed significant
31 differences comparing the means pre- and post-treatment in these variables (*:
32 $0.05 > p > 0.01$; **: $0.01 > p > 0.001$; ***: $0.001 > p$).