


REVIEW ARTICLE

Minimal invasiveness in vertical ridge augmentation

Istvan Urban^{1,2} | Eduardo Montero^{3,4} | Ignacio Sanz-Sánchez^{3,4} | David Palombo⁴ | Alberto Monje^{1,5}  | Grazia Tommasato⁶ | Matteo Chiapasco⁶

¹Department of Periodontics and Oral Medicine, University of Michigan, Ann Arbor, Michigan, USA

²Private Practice, Budapest, Hungary

³EETP (Etiology and Therapy of Periodontal and Peri-Implant Diseases) Research Group, University Complutense, Madrid, Spain

⁴Section of Postgraduate Periodontology, University Complutense, Madrid, Spain

⁵Department of Periodontology, Universitat Internacional de Catalunya, Barcelona, Spain

⁶Unit of Oral Surgery, Department of Biomedical, Surgical, and Dental Sciences, A.O. Santi Paolo & Carlo, Dental Clinic, University of Milan, Milan, Italy

Correspondence

Eduardo Montero, Faculty of Odontology, University Complutense of Madrid, Madrid, Spain.

Email: eduardomonterosolis@ucm.es

1 | INTRODUCTION

The term “minimally invasive surgery” first entered the medical literature in 1990, and since then minimally invasive surgery has been applied with the aim to better preserve structures and function, providing methods to optimize surgical results with less operative trauma and, consequently, minimizing patient discomfort.^{1,2}

This requires the development of specific methods of preoperative imaging, planning, intraoperative navigation, and special surgical instrumentation. These approaches are quickly evolving thanks to progressively more precise surgical procedures in association with smaller incisions compared with those traditionally used.³

The concept of minimally invasive surgery can also be applied in the field of maxillo-mandibular bone regeneration/reconstruction and has become a particularly interesting challenge for clinicians in the last few years. The aim of minimally invasive surgery is, on one hand, to simplify procedures and to reduce morbidity and invasiveness for patients, and, on the other hand, to provide the same effectiveness in terms of functional and aesthetic outcomes.

In the case of vertical bone defects in patients in need of implant-supported prosthetic restorations, the challenge becomes even more complex because vertical ridge augmentation aims to achieve bone regeneration without osseous wall containment. Consequently, the elevation of an adequately sized flap, the releasing incisions to allow a tension-free suture, the need for an adequate quantity of autogenous bone, and certain surgical skills, are mandatory to decrease

intraoperative and postoperative complications,⁴ but may be in conflict with the concept of mini-invasiveness.

In order to reduce morbidity and complications (such as infection, dehiscence, and neural damage) and to simplify procedures, the use of short implants have been proposed, with acceptable clinical results.⁵⁻⁷ However, when short implants do not guarantee an adequate functional and/or aesthetic result, or they cannot be used because of insufficient residual bone volume, the reconstruction of hard and soft tissues in edentulous areas affected by severe bone defects is mandatory before implant placement.

Different bone reconstructive or regenerative techniques have been proposed: (i) distraction osteogenesis⁸⁻¹⁰; (ii) maxillary sinus floor elevation^{11,12}; (iii) onlay grafts with intra-oral and extraoral autogenous bone blocks¹³⁻²¹; (iv) guided bone regeneration with resorbable or nonresorbable membranes (polytetrafluoroethylene)^{4,22} in association or not with tenting screws; and (v) protected bone regeneration with noncustomized²³⁻²⁶ or customized titanium meshes.²⁷⁻³⁰

All the aforementioned surgical techniques require special skills and the results are very technique sensitive.³¹ Distraction osteogenesis, even if it makes it possible to correct relevant vertical defects, is limited to “pure” vertical augmentation and requires nonnegligible compliance of the patient. Onlay grafting with autogenous bone blocks still represents a versatile and well-documented procedure that enables the correction of any type of defect, with no limitations as regards the extent of the defect. However, the increased

This is an open access article under the terms of the [Creative Commons Attribution](https://creativecommons.org/licenses/by/4.0/) License, which permits use, distribution and reproduction in any medium, provided the original work is properly cited.

© 2023 The Authors. *Periodontology 2000* published by John Wiley & Sons Ltd.

morbidity resulting from a frequent "second" surgical site (donor and recipient site) must be taken into consideration, and the modeling and fixation phases of the blocks require specific expertise.¹⁴⁻¹⁶ Also, guided bone regeneration represents a well-documented procedure: according to the extent of the vertical defect, guided bone regeneration can be performed using autogenous bone particles or bone substitutes in association with resorbable or nonresorbable membranes. However, it is worth noting that the use of resorbable membranes, because of their insufficient space-maintaining capacity, might be inadequate for relevant vertical defects. Conversely, nonresorbable membranes offer a very good space-maintaining effect, but are prone, in the case of exposure, to a nonnegligible risk of infection, which may compromise the amount of regeneration.^{14,17,32} Moreover, nonresorbable membranes must be trimmed and modeled "in situ" to be adapted to the defect, thus requiring specific skills. Finally, titanium meshes have shown good clinical and radiological results, even if the traditional ones must be trimmed and curved according to the defect to be reconstructed, thus lengthening surgical times and requiring surgical experience. Moreover, titanium meshes may undergo exposure (with or without infection) and may be difficult to remove (because of the growth of bone over the mesh or penetration of the inner layer of the soft tissues into the "open" structure of the mesh).²³⁻²⁶

To minimize complications and postoperative morbidity, different modifications to conventional augmentation methods have been suggested in the last two decades, including: (i) the use of soft tissue expanders prior to bone grafting^{33,34}; (ii) the cortical tenting technique³⁵; (iii) the split bone blocks technique^{36,37}; (iv) the tunnel technique^{36,38}; (v) the computer-guided bone harvesting procedure³⁹; (vi) the use of a three-dimensional-printed bone model to preshape or produce bone blocks⁴⁰⁻⁴⁵ or to preshape or produce customized titanium meshes^{27-30,46}; (vii) the split-thickness flap design without vertical releasing incisions^{47,48}; (viii) the vestibular shifted flap design⁴⁹; and (ix) tissue engineering and cell therapy.^{50,51}

The aim of this review is to describe the most recent surgical strategies used in vertical bone augmentation to reduce the invasiveness and complications, as well as to improve patient-reported outcome measures. Even although this is a narrative review, a systematic electronic search was performed to analyze comprehensively the scientific literature available in order to cover all the potential manuscripts proposing minimally invasive reconstructive approaches in the treatment of vertical ridge deficiencies.

2 | ELECTRONIC SEARCH

The eligibility criteria for the search were: (i) interventions aiming for vertical ridge augmentation; and (ii) randomized controlled trials, CCTs, and prospective/retrospective case series with a minimum of 10 patients (five per group in controlled studies) with at least data for reentry/implant placement/implant loading.

The electronic search was performed in Medline via PubMed. The search was limited to human subjects and to studies reported

in English. The search strategy was the same as the one previously used for the European Workshop of Periodontology on Bone Regeneration in the systematic review evaluating the effectiveness of vertical ridge augmentation interventions,⁵² adding the term "minimal invasiveness" (ie, [Medical Subject Headings terms]: Alveolar bone loss OR Alveolar bone atrophy OR [Text Words, Title]: ridge atrophy OR ridge atrophies OR ridge deficiency OR ridge deficiencies OR vertical ridge deficiency OR vertical ridge deficiencies OR alveolar ridge atrophy OR alveolar ridge atrophies OR vertical ridge atrophy OR vertical ridge atrophies OR bone atrophy AND [Medical Subject Headings terms]: Alveolar ridge augmentation OR bone regeneration OR bone grafting OR bone replacement material OR [Text Word, Title]: vertical bone augmentation OR vertical ridge augmentation OR vertical ridge regeneration OR vertical bone regeneration OR vertical alveolar ridge augmentation OR vertical alveolar ridge regeneration).

The initial electronic search identified 274 records in PubMed. However, after screening for title and abstract, only two manuscripts focused on minimally invasive approaches in vertical ridge augmentation.⁵³⁻⁵⁵ Therefore, we decided to remove the term "minimal invasiveness" from the search strategy and update it from January 2018 to July 2021.

The second electronic search yielded 401 articles published since January 2018. After abstract screening and full-text evaluation, 16 manuscripts fulfilled the inclusion criteria. However, it should be noted that most of these manuscripts did not describe any particular technique that could be considered "minimally invasive", nor evaluate patient-reported outcome measures. Therefore, in this review we only consider those manuscripts resulting from our search and the one for the XV European Workshop on Periodontology that propose reconstructive approaches that may be considered minimally invasive or that propose innovative surgical techniques (eg, subperiosteal tunnels, soft tissue expanders, tent pole technique, etc.), devices (eg, customized meshes or xenograft/allograft blocks), or adjuncts (eg, growth factors, cell therapy) that may end up in less morbidity for the patient, independently of whether it was properly evaluated or not. Further considerations related to preoperative and/or diagnostic examinations, the incidence of complications and associated morbidity, and the factors influencing the long-term results of vertical ridge augmentation procedures, are presented.

3 | EVALUATION OF PROPOSED SURGICAL TECHNIQUES AND DEVICES IN TERMS OF THEIR MINIMAL INVASIVENESS

Vertical ridge augmentation per se is a complex treatment modality that somehow requires certain invasiveness. However, to minimize invasiveness, different strategies can be considered to reduce the risk of complications, improve the patient-related outcomes, and to optimize treatment success.

3.1 | Diagnostic phase and patient preparation

Before undergoing any vertical bone augmentation procedure, a meticulous diagnosis and proper patient preparation should be considered as part of a successful treatment-planning protocol to avoid or minimize the onset of complications associated with bone augmentation procedures.⁵⁶ In the treatment of complex cases, we need to evaluate the objective of the regenerative approach and determine if there are other less invasive alternatives (eg, short implants) that may produce similar treatment outcomes. This is especially relevant in the case of vertical defects, because the more extensive the defect is, the greater the risk of complications.⁴ Therefore, the evaluation of bone availability is one of the first steps that should be carried out to determine whether we need to perform a vertical bone augmentation procedure.

The introduction of new technologies and software allows us to be very accurate in the estimation not only of the residual bone, but also to evaluate the amount of bone that a potential donor site would provide if needed.⁵⁷ Moreover, the possibility of merging the information about the available bone with the planned prosthetic restoration, gives us an opportunity to predict very precisely the type of bone augmentation procedure needed, the amount of bone to be gained, and the expected aesthetic outcomes.⁵⁸ Therefore, the use of these available tools is highly recommended when planning a vertical ridge augmentation procedure to provide an overview of what we can reach and what we need to do, and also to choose the least invasive treatment option.

Patient preparation is also an important step before undertaking any vertical augmentation procedure. First, it is crucial to eliminate any source of potential infection, such as untreated caries, endodontic pathology, or active periodontitis, because it is very important to prevent postoperative complications.⁵⁹ Also, before starting any complex bone augmentation procedure, we must consider the extraction of teeth with a hopeless prognosis or teeth that might have disease recurrence and are close to the regenerated area.³¹ Moreover, patients should only receive surgery if they display high standards of oral hygiene.⁶⁰ From the patient perspective, smoking cessation is highly recommended, because smoking may be associated with a higher risk of complications⁶¹ and peri-implantitis, especially in the scenario of bone augmentation procedures.⁶² Several medical conditions may alter healing of the soft and hard tissues, such as diabetes, in which an impaired healing capacity, ossification deficiencies, and vascular alterations are present.^{63,64} Therefore, diabetic patients should maintain strict glycemic control⁶⁵ and patients and clinicians should be aware that major augmentation procedures present an increased risk of failure in this cohort of patients.⁶⁶

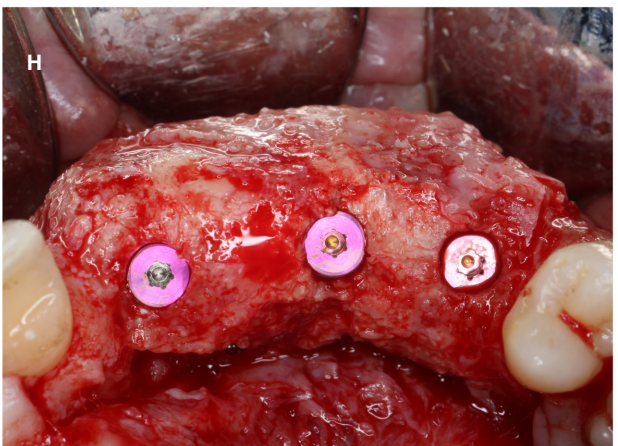
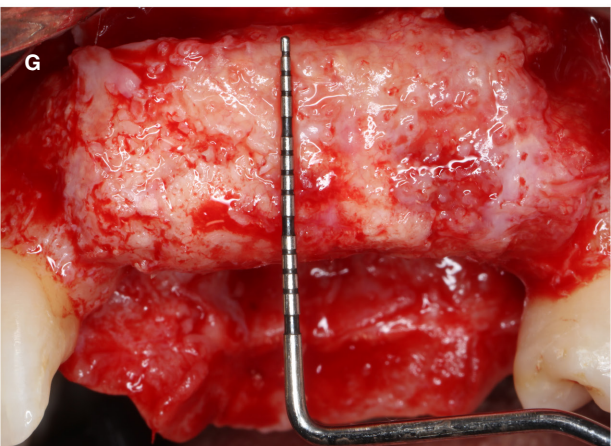
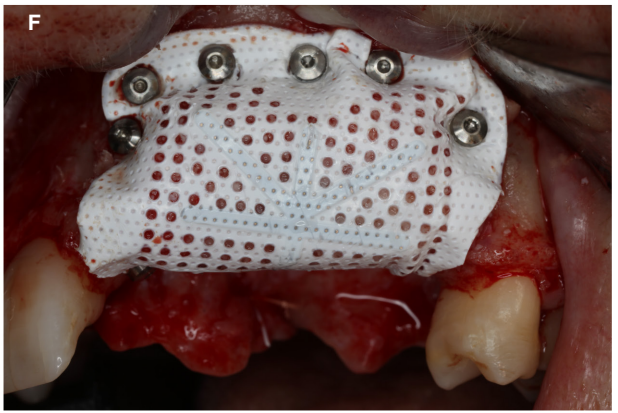
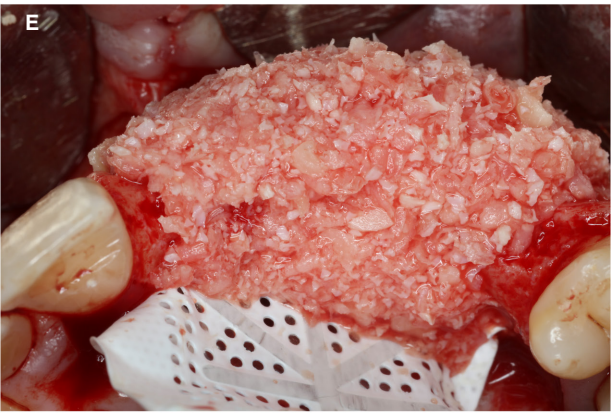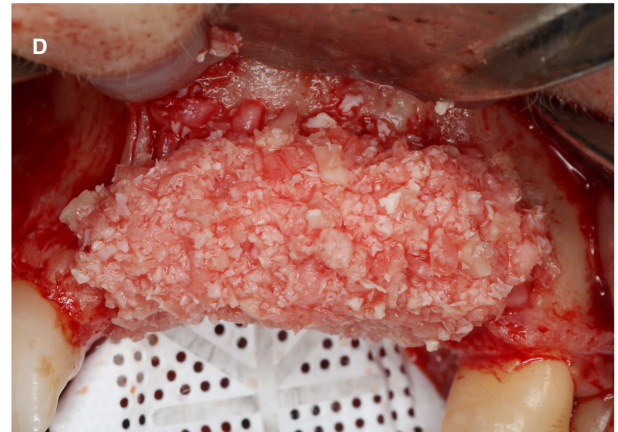
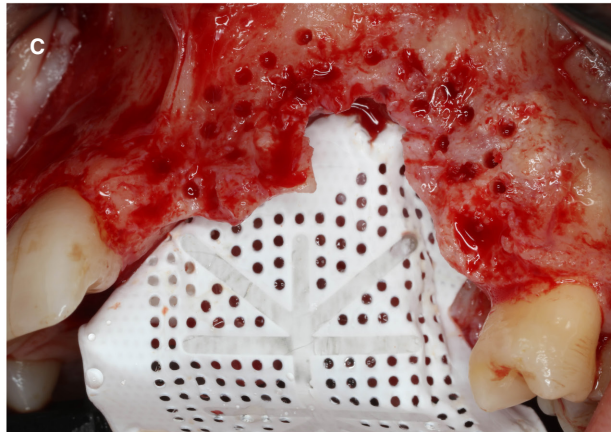
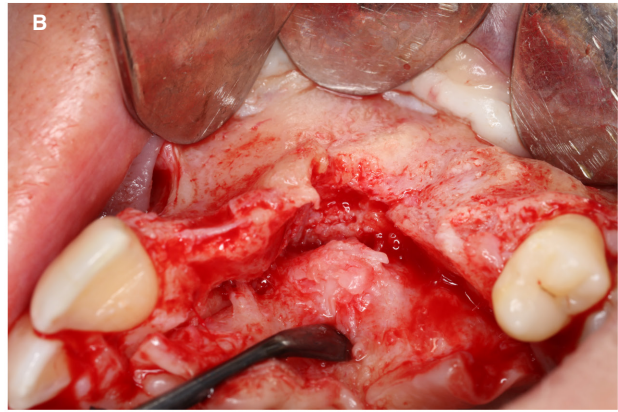
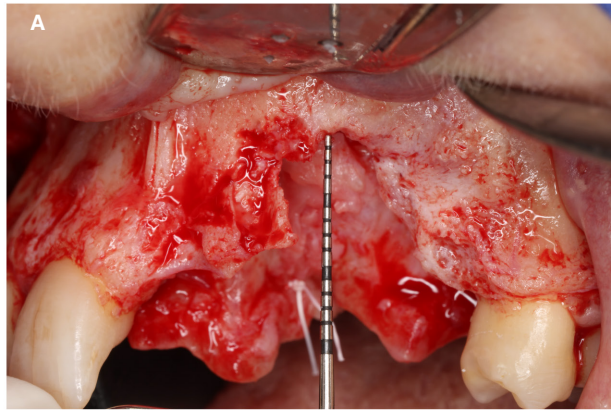
To achieve success together with less invasiveness, vertical bone augmentation procedures should be performed by well-trained and experienced surgeons. The clinician should carefully follow each step with special attention during flap management and suturing, because it is crucial that the stabilized bone regenerative materials remain covered by the soft tissues.⁶⁷ In any case, it is important to follow the recommendations described for each individual technique and to acquire the proper learning curve to achieve successful results with minimal inconvenience for patients.

3.2 | Modification of surgical techniques

Several modifications to the surgical techniques have been proposed to reduce and minimize invasiveness and the risk of postoperative complications. Vertical ridge augmentation is more challenging than horizontal ridge augmentation because it requires advanced flap management and uncompromised soft tissue coverage of the wound to protect the grafts and to support supracrestal blood clot stabilization.⁶⁸ If properly executed, the conventional full-thickness flap design with vertical and horizontal releasing incisions results in tension-free wound closure and subsequent primary intention wound healing (Figure 1), although membrane exposure and/or graft infection is a well-documented complication of this approach.^{52,59} As an alternative to the conventional approach, a minimally invasive split-thickness flap without periosteal releasing incisions has been proposed, which could have the same results in a tension-free wound closure, but at the same time avoiding the aforementioned adverse events related to full-thickness flaps.⁴⁷ Briefly, the technique consists of a partial-thickness incision used to separate the mucosal layer of the flap from the periosteal layer on the alveolar ridge. The periosteal layer is reflected and used to stabilize the regenerative site using periosteal sutures. This so-called double-flap incision technique was demonstrated in a clinical trial to obtain greater flap advancement with less patient morbidity (pain and swelling as evaluated by a visual analog scale at 7 days postoperatively) than with conventional periosteal releasing incision techniques.⁴⁷ However, some concerns may arise from this surgical approach. First, it is probably more demanding for the average clinician. Second, it is unlikely that in major vertical ridge augmentation the periosteum will be able to cover the entire graft/membrane.

Another approach that has been described to reduce the invasiveness of vertical ridge augmentation by means of guided bone regeneration is the split thickness flap design without vertical releasing incisions.^{48,69} The technique consists of a midcrestal incision on the keratinized mucosa that is continued intracrevicularly at the

FIGURE 1 Representative case of a patient presenting with an anterior maxillary vertical defect. A and B, Labial and occlusal views of an advanced vertical and horizontal defect. C–F, Labial and occlusal views of a particulated bone graft immobilized with a perforated d-PTFE membrane. A 1:1 ratio of intraoral autogenous particulated bone graft mixed with a xenogenic bone graft (ABBM) was utilized. G and H, Labial and occlusal views of regenerated bone during membrane removal. Three implants were placed into the newly formed bone. ABBM, anorganic bovine bone mineral; d-PTFE, dense polytetrafluoroethylene



two adjacent teeth mesially and distally both buccally and orally. In the case of posterior edentulism, the midcrestal incision line length is two-thirds of the entire surgical area, and one-third length is continued mesially to the neighboring two teeth. No vertical releasing incisions are performed and therefore there is less reduction in blood supply, which may affect graft ossification and increase remodeling capacity.⁷⁰ A full-thickness buccal flap is reflected with elevators up to the mucogingival line, followed by split-thickness mucosal flap preparation over the mucogingival line. Subsequently, the underlying periosteal layer is elevated from the bone surface. After the bone augmentation procedure has been carried out, a double-layer suturing is performed using horizontal mattress sutures in order to cover the membrane with the periosteal layer, and a combination of horizontal mattress and noninterrupted sutures are used to close the mucosal layer and reach a tension-free wound closure.⁴⁸ The main advantage of this procedure seems to be the bilaminar wound closure, leading to a tension-free flap adaptation, thus minimizing postoperative complications related to wound dehiscence. In this prospective case series, the split-thickness flap design represented an approach leading to favorable wound healing with low patient morbidity and a low rate of membrane exposure (4.2%). However, in most of the cases included in this review the amount of vertical ridge augmentation was minimal because they were mostly dealing with horizontal defects. Furthermore, it is an open question how effective it is to split flaps in thin phenotype patients, as this may lead to flap necrosis.

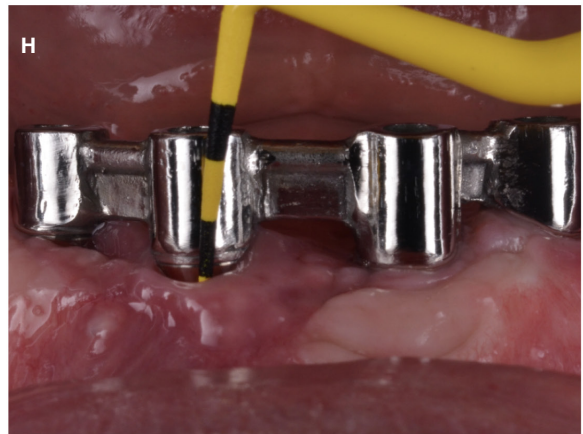
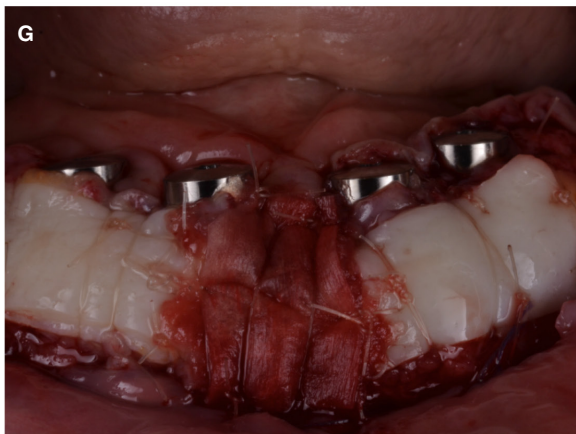
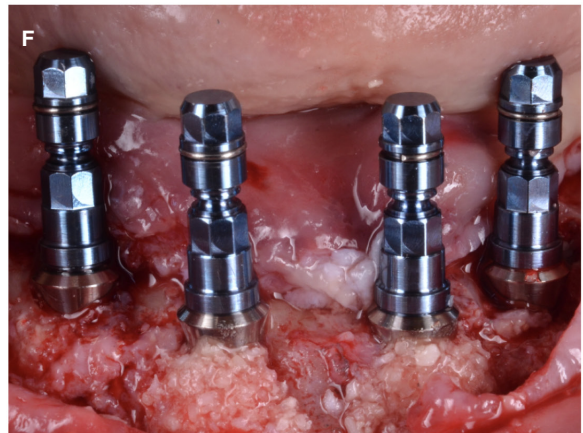
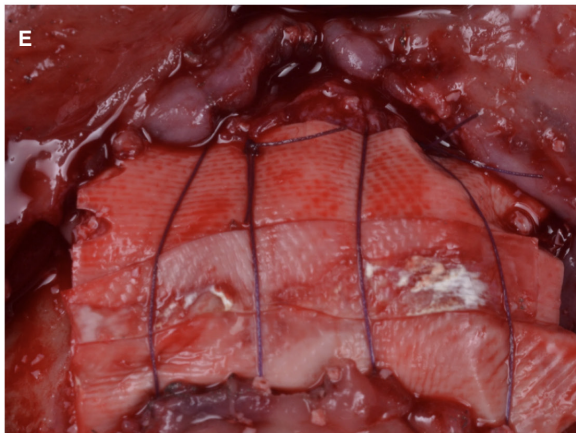
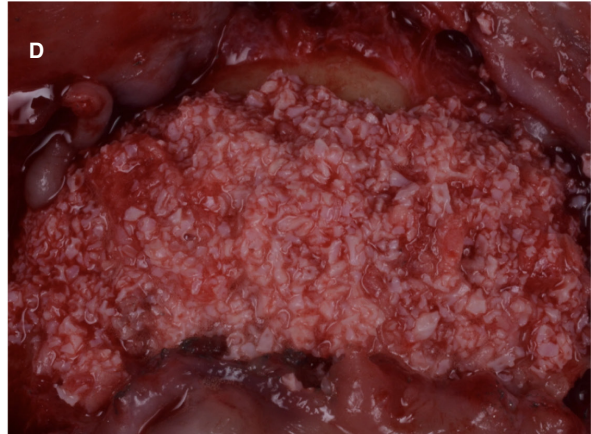
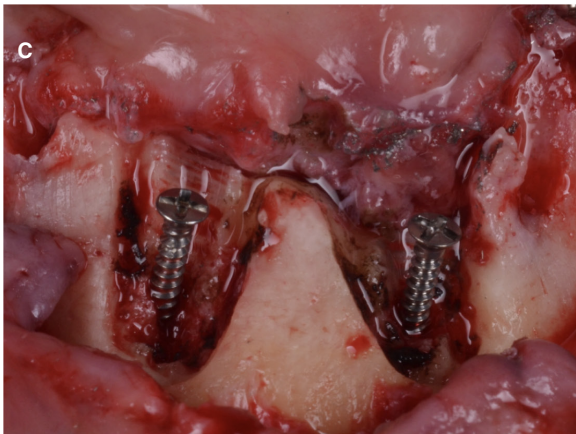
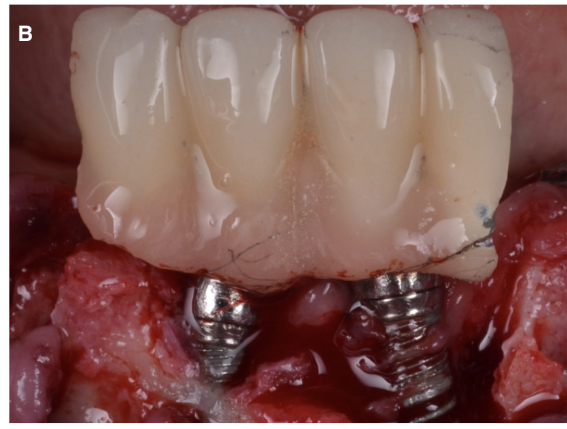
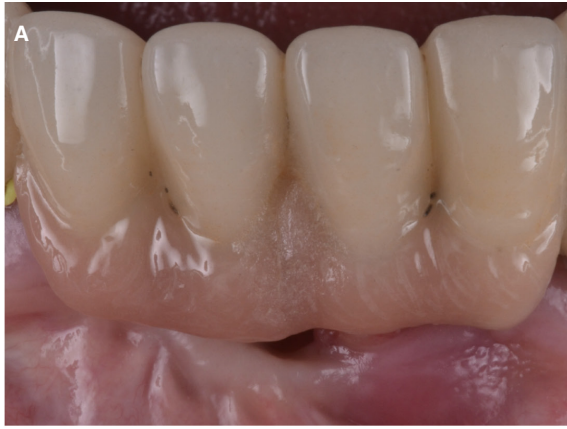In the field of autogenous bone blocks, the "three-dimensional" reconstruction or shell technique has been proposed.^{36,37} Thin cortical bone blocks are initially used to restore the contours of the alveolar ridge and the remaining gaps are then filled with autogenous bone chips. The resulting accelerated vascularization in the container and the volume stability of the avascular cortical bone plate reduces bone resorption to less than 10%, so the alveolar ridge contour can be restored with a predictable outcome. The short- and long-term results after augmentation with the aid of the shell technique demonstrated low complication rates and excellent volume stability, even 10 years after surgery.³⁷ The main advantage of this technique is that the grafts are harvested from the external oblique ridge with a micro saw, making the procedure very safe and with a low risk of complications. Moreover, because the bone block is split into two thin plates that will serve to prepare the external walls of the regeneration area, the amount of bone block to be harvested can be reduced considerably, making the procedure much less invasive.

To further reduce the invasiveness of this technique, different modifications have been introduced, such as the tunnel technique.³⁸ The idea is to prepare a tunnel, allowing the maintenance of the integrity of the soft tissue over the graft material. This approach was studied in a prospective case series including 10 patients that evaluated vertical bone augmentation with autogenous bone block grafts following the tunnel technique. The block was harvested from the external oblique ridge with the conventional technique. In the recipient area, a single vertical incision was made at the distal margin of the mesial tooth to the defect. This incision extended over the mucogingival junction. Through this single vertical incision, a full-thickness flap was raised buccally and lingually, tunneling the mucosa and the attached gingiva over the defect and reaching the distal portion of the defect. Once the soft tissues were prepared, the first thin bone plate was fixed with titanium screws and stabilized in such a way to create a bone bridge between the mesial and distal bone peaks. The second thin bone block was fixed laterally with a titanium screw, closing access to this space once the remaining gaps were filled with autogenous bone chips. No barrier membranes were used. After 4 months of healing, no complications were registered, and the mean vertical bone gain was 6.00 ± 1.29 mm.

The cortical tenting technique³⁵ and the tent pole technique⁷¹ have been proposed to increase the ridge width or height using autologous bone blocks or a combination of bone substitutes together with a barrier membrane. Both techniques seek to preserve the space for bone augmentation; in this way the titanium screws maintain this dimension by decreasing the pressure of the overlying soft tissue on the graft, preventing its migration and resorption. These techniques may diminish the invasiveness of the procedure if it is used with resorbable collagen membranes, and is able to achieve vertical ridge augmentations of approximately 4.3 mm⁵² (Figure 2). However, it should be noted that if major augmentations are sought, the use of nonresorbable membranes or the shell technique with autogenous bone plates is encouraged.

Because wound dehiscences are one of the most common complications of horizontal and vertical ridge augmentation procedures, soft tissue management is a crucial aspect that impacts upon the outcome of these surgeries. Frequently in reconstructive procedures, an optimal wound seal is obtained using two suture planes to secure a deep and a superficial closure by horizontal mattress sutures and single simple sutures. As the palatal flap eversion to couple the first 4-5 mm of the buccal flap may be difficult because of the characteristic dense connective tissue of the area, a new technique named vestibular shifted flap design has been proposed.⁴⁹ In this

FIGURE 2 Vertical and horizontal ridge augmentation to handle the sequelae of peri-implantitis by means of guided bone regeneration via resorbable membrane. A, Patient presenting with stage IV periodontitis and peri-implantitis in the anterior mandible. B, Note the severity of peri-implantitis. After implant removal with a trephine and reverse torque, an alveolar ridge defect is identified that precludes oral rehabilitation with dental implants. C, Tenting screws were placed to support the long-lasting resorbable barrier membrane. D and E, A mixture of particulate autogenous bone harvested from the posterior mandible and anorganic bovine bone mineral together with a crosslinked collagen membrane was secured by means of a subperiosteal suture and was used to fulfill the principle of compartmentalization. F, Four implants retaining an overdenture were placed, achieving adequate primary stability 5 months after guided bone regeneration. G, Two months later, free epithelialized mucosal grafts were placed at the buccal aspect during second-stage surgery. H, Peri-implant health and stability are noted at the 12-month follow-up



technique, the incision line is shifted towards the buccal side based on defect anatomy and the target of vertical bone augmentation; in this way the palatal flap length extends at least 4 mm coronal to the bone graft level prior to wound closure. This approach may impact invasiveness because it is expected that the optimal adaptation of the inner faces of the flaps results in a lower risk of nonprimary wound healing.

The use of soft tissue expanders for vertically atrophied alveolar ridges has been proposed prior to bone grafting.³³ The rationale behind their use is to increase the soft tissue volume before bone grafting allowing for a sufficient amount of soft tissue, enabling better graft coverage, which will lead to a more stable and effective vertical bone augmentation procedure. Furthermore, several studies demonstrated that soft tissue expansion improved microcirculation, and more rapid osseointegration and even new bone formation around the expander have been reported in cases of a slowly expanding periosteum.⁷² The use of soft tissue expanders has been evaluated in a multicenter randomized clinical trial and compared with conventional guided bone regeneration to treat vertical ridge deficiencies.⁷³ Patients in the experimental group received a hydrogel type, a self-inflating soft tissue expander that was in place for 28 days. After the 1-month expansion period, the expander was removed, and bone grafting was performed with the tunneling method without full flap reflection using a resorbable membrane together with a xenograft. For the control group, the conventional guided bone regeneration technique with sufficient periosteal-releasing incisions was performed to achieve a tension-free wound with primary closure. The results showed that the expander had to be removed in only one out of 23 cases. Moreover, early wound dehiscence after bone grafting did not occur in this group. On the contrary, two out of 23 cases in the control group experienced wound dehiscence. Six months after the reconstructive procedure, vertical bone gain was significantly greater in the experimental group (5.12 ± 1.25 compared with 4.22 ± 1.15 mm) and graft contraction significantly less (30.7% compared with 55.1%).⁷³

3.3 | Staged or simultaneous implant placement?

In theory, the invasiveness of vertical ridge augmentation interventions may be limited by reducing the number of surgical interventions, that is, placing implants simultaneously to the ridge augmentation. However, when evaluating the effectiveness of different vertical ridge augmentation procedures in a recent systematic review, the weighted mean effect of the simultaneous approach was 3.81 mm, while the staged approach achieved a weighted mean effect of 4.39 mm. This may imply that the amount of augmented bone is somehow limited on simultaneous interventions or that these procedures are carried out whenever the required augmentation is more limited. In any case, the invasiveness is also related somehow with the severity of the complications that may occur. Frequently, graft/membrane exposures and postoperative infections may lead to a bacterial contamination of adjacent implant surfaces if a

simultaneous technique is utilized and also in cases of simultaneous vertical ridge augmentation. For this reason, a staged approach is preferable whenever there is an important amount of missing bone, the ideal position of the implant according to the future restoration is outside the bony envelope, or primary stability is compromised, especially in the hands of unexperienced clinicians.

3.4 | Digital tools and materials

With the advent of new technologies, bone grafting procedures have become more efficient, not only in terms of surgical treatment time, but also in relation to patient morbidity.⁷⁴ Digital tools can be very useful during the diagnostic phase, treatment planning, and surgical execution. Today, there is software available that can simulate the amount of bone needed, predicting accurately the bone volume to be gained. This can help the clinician to select the best donor site, to help the patient understand the objective of the treatment, and even to estimate the costs more precisely.

One available digital tool is to transform the Digital Imaging and Communications in Medicine files from the cone beam computed tomography into STereoLithography files or another printable format. By doing this, a printed model of the bone was very easily obtained. Again, this can be useful to help the patient understand the type of bone defect and the aim of the procedure. Furthermore, surgical and prosthetic phases can be virtually simulated by importing three-dimensional data into implant planning software, and ideal implant positions could be planned before surgery according to bone quality and quantity, the location of anatomic structures such as nerves, vessels, and sinuses, as well as prosthetic demands and aesthetic evaluations.^{75,76} Specifically, computer-guided implant placement may be advantageous in cases of limited bone availability, combining the effects of virtually-aided guided bone regeneration and computer-guided implantology.⁷⁷

Also, it has been proposed that the printed model can be used to trim and preform a titanium mesh before the augmentation procedure.⁷⁴ Traditional titanium meshes have been shown to be effective when used to vertically augment the ridge defect, although some drawbacks and complications have been reported.²³ First, the mesh usually has a rectangular shape and must be trimmed and bended according to the defect morphology, requiring clinical skills, expertise, and plenty of time. Furthermore, irregular and sharp angles and edges may be created during modeling, which may expose soft tissues to mechanical trauma, leading to perforation of the flap and exposure of the mesh. This can be followed by infection and partial or total loss of the initial bone augmentation.

To overcome these disadvantages, laser sintering has been proposed to produce customized titanium meshes by means of computer-aided design/computer-aided manufacturing technology (Figure 3). Its main advantages are the fabrication of meshes with smooth edges, better adaptation to the bone defect, and the possibility of including individual design modifications that can improve all aspects of ridge augmentation procedures, such as guidance

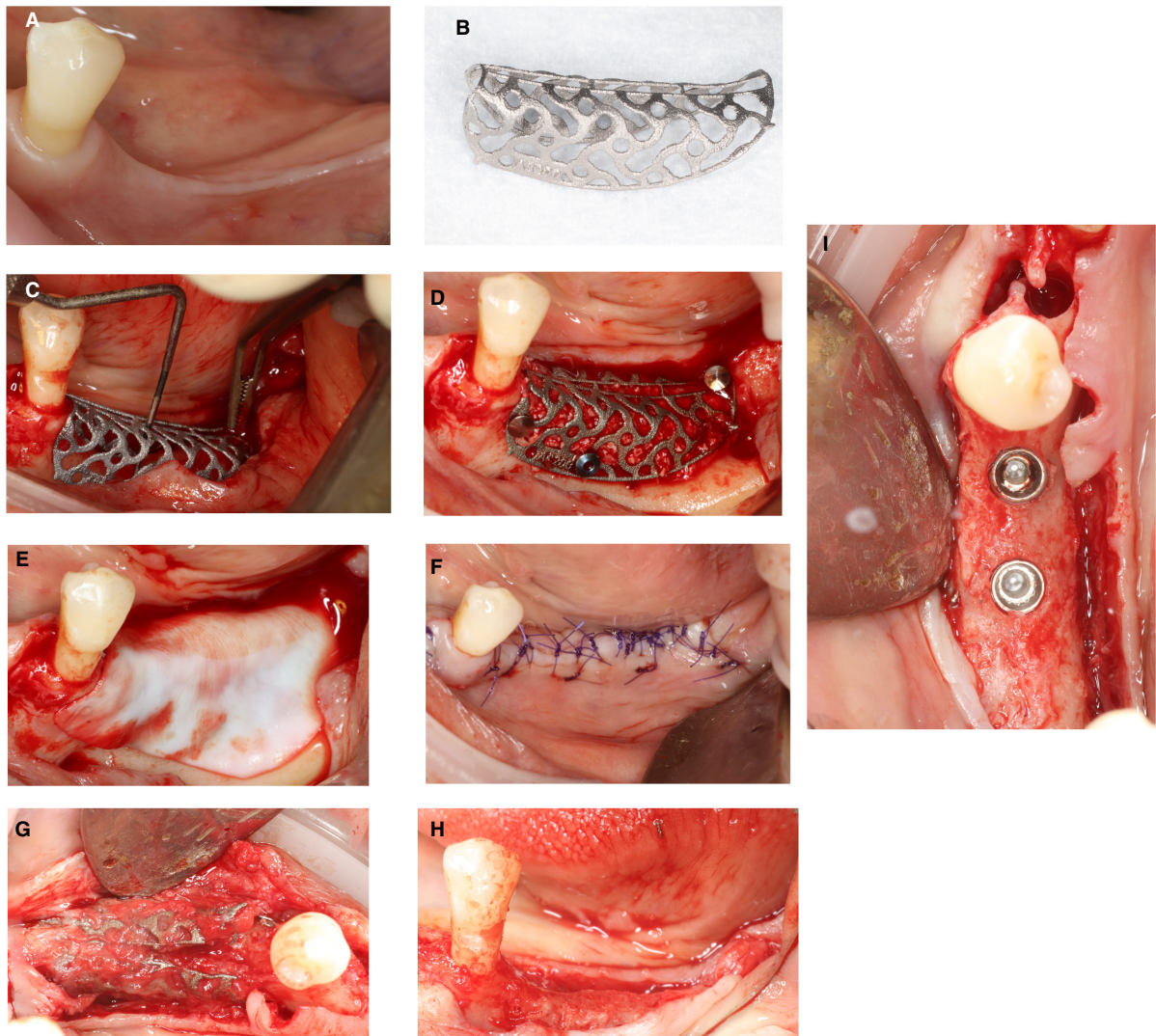


FIGURE 3 Representative case of the use of a customized titanium mesh. Patient presenting with a vertical bone deficiency in the posterior mandible. A, Buccal view of the posterior area of the third sextant in which the vertical ridge defect can be appreciated. B, Customized printed titanium mesh. Titanium mesh placed above the defect. C, Vertical bone gain of 5 mm was planned. Titanium mesh was fixed in its place using titanium pins. D, A mix of autologous particulated bone and xenograft was used to fill the mesh. E, A resorbable native collagen membrane was used to cover and protect the titanium mesh. F, Suture of the flaps using horizontal internal mattress sutures and single sutures. G, Reentry at 8 months after the augmentation procedure. The titanium mesh can be broken at the middle portion to facilitate its removal. H, Buccal view of the posterior third sextant in which the vertical defect has been completely regenerated. I, Occlusal view of the ridge with 8-mm length implants inserted

regarding where the implants should be placed during the second stage of surgery.^{30,78} Further advantages could consist of a decrease in surgical time, providing an estimate of the amount of bone needed to reconstruct the defect, and a reduction of invasiveness because we can prelude flap extension and anatomic landmarks. This procedure was evaluated in a prospective case series including 21 patients and 30 implant sites. During healing, two mesh exposures occurred and, after removing the exposed part, healing was uneventful. Vertical bone gain above the implant platform was 1.4 mm (the average vertical bone gain was 2.5 mm), while the average thickness of the buccal bone width at the implant platform was 2.0 mm (the average horizontal bone gain was 4.1 mm). To evaluate the feasibility and accuracy of this technology, an accuracy assessment of

this digital solution was conducted. Through the volume analysis of virtual augmentation and actual augmentation, the accuracy of this procedure reached 95.82% (ranging from 88.53% to 99.15%).⁴⁶ A recent retrospective study also evaluated the use of customized titanium meshes to treat vertical ridge deficiencies in 41 patients.²⁹ According to the results, this mode of therapy represents a safe and reliable tool for guided bone regeneration of severely atrophic sites, with simplification of the surgical phases. The applicability of this technique could also be extrapolated to the use of preshaped non-resorbable membranes.

Especially interesting is a recently published randomized controlled trial assessing three-dimensional bone augmentation of severely atrophied maxillary alveolar ridges using prebent titanium

meshes or customized poly-ether-ether-ketone meshes.⁷⁹ In this study, Digital Imaging and Communications in Medicine files of both groups were imported into specialized software that allowed the design of the virtual three-dimensional increment of the deficient ridge, and three-dimensional printing technology was used to fabricate the virtually grafted stereolithographic model used for prebending the titanium mesh (control group) or a printed and customized poly-ether-ether-ketone meshwork designed with a 2-mm thickness covering the buccal, crestal, and palatal surfaces of the alveolar bone leaving the space for the grafted area (test group). Wound healing was uneventful in all cases except for once in each group (ie, one out of eight cases in each group) and no differences were observed among them regarding the vertical bone height obtained. Preshaping the titanium mesh or printing a poly-ether-ether-ketone mesh could reduce the invasiveness of vertical ridge augmentation procedures because conforming titanium meshes or nonresorbable membranes is time consuming during the surgical interventions. Common complications associated with the use of titanium meshes are mesh exposure resulting from their stiffness and difficulties in the removal process. These limitations may be overcome by using poly-ether-ether-ketone or other biocompatible materials, which have been widely used in orthopedic and trauma surgery,⁸⁰ although their efficacy in vertical ridge augmentation requires further assessment.

Computer-guided can also be helpful in the bone harvesting procedures required for the shell technique to reduce the risk of anatomic structural damage at the donor site.³⁹ The technique starts using planning software that allows visualizing the anatomic structures, such as the alveolar canal, the mental foramina, the mental nerve, and the teeth roots present in the donor site. Through each cross-sectional image, ideal bone-cutting planes are defined taking into consideration the aforementioned anatomic structures. Then the bone block length, height, and thickness are defined. Once the cutting planes are established, their projection outside the bone/body surface defines the internal faces of the surgical guide. Each face guides the cutting tool direction once the tool is simply leaning against the surface of the surgical guide that has been printed and fixed with mini screws. The osteotomy can be performed with a piezoelectric instrument, which may be safer than with a micro saw. As the cutting direction and the working depth are unequivocally defined by the surgical guide, the risk of injuring important anatomic landmarks disappears. The results from a case series showed that this procedure was safe with no complications reported.³⁹

Another applicability of a three-dimensional-printed bone model is to preshape a bone block graft and to plan the fixation screws. The main advantages of this technique are a reduction in time and the ease of graft adaptation. The feasibility and security of this procedure have been reported in several clinical studies, which have also confirmed the related advantages when using allogenic bone blocks manually milled before surgery.^{40,42}

The same application has been suggested with the use of synthetic grafts together with the shell technique. In summary, a virtual ridge augmentation of a maxillary defect is carried out, and a

three-dimensional-printed model is utilized chairside for extraoral thermic bending and trimming of an absorbable shell graft (poly-D, L-lactic acid polymer). Then the tunnel technique is used to fix the shell with osteosynthetic screws, and a mixture of autologous bone chips and xenograft is used to fill the spaces.⁸¹ The invasiveness of the shell technique can also be reduced by using allogenic bone plates, with similar results compared with autogenous bone, provided autologous bone chips are used to fill the bony envelope.⁸² Whether, xenografts, and/or synthetic grafts without any addition of autogenous bone is sufficient to lead to vertical ridge augmentation appears to be unlikely from the perspective of biological plausibility. Specifically, because the aim of vertical ridge augmentation is to achieve bone augmentation in the absence of osseous wall containment, angiogenesis must reach a certain distance from preexisting bone, in a way the use of the only graft able to ensure osteogenesis (i.e. autogenous bone) is desirable, which just does not mean that other bone substitutes such as xenografts may be useful due to their osteoconductive properties in order to reduce the amount of autogenous bone to be retrieved.

The reconstruction of the alveolar ridge dimensions can also be performed digitally, and the graft digitally designed and manufactured by a milling process. This workflow eliminates the requirement for a physical alveolar ridge defect model. One possible way is to mill bone blocks. This approach has been utilized with different graft origins, such as allogenic,⁴⁵ alloplastic,⁴³ or xenogenic.⁴⁴ The main advantage when using this customized bone blocks are time reduction, since graft adaptation is much easier, decreased morbidity and increase fitting accuracy of the graft (Figure 4). One clear advantage of computer-aided design/computer-aided manufacturing technology for block grafts over three-dimensional printing is its potential application in a wide range of grafting materials.

Three-dimensional printing has also been developed to produce customized bone blocks from a synthetic origin.⁴³ The advantages associated with this technique include unlimited availability, no risk of disease transmission, high patient acceptance, reduced waste of biomaterials, an ability to optimize surface topography and macroporous architecture, and a reduction of the intraoperative time. However, most of the evidence is from preclinical studies in animal models and further research in clinical studies is needed to evaluate the real impact of these grafts as an alternative to conventional therapies.⁸³

3.5 | Tissue engineering and cell therapy

The future in bone augmentation procedures is tissue engineering. This is a discipline employing the principles of engineering and biological sciences for the fabrication of functional constructs used to restore, maintain, or improve tissue functions. Growth factors incorporated in carriers, stimulation of selective production of growth factors using gene therapy, and the delivery of expanded cellular constructs (ie, cell therapy) have been developed for craniofacial regeneration, including vertical ridge augmentation.⁵⁰

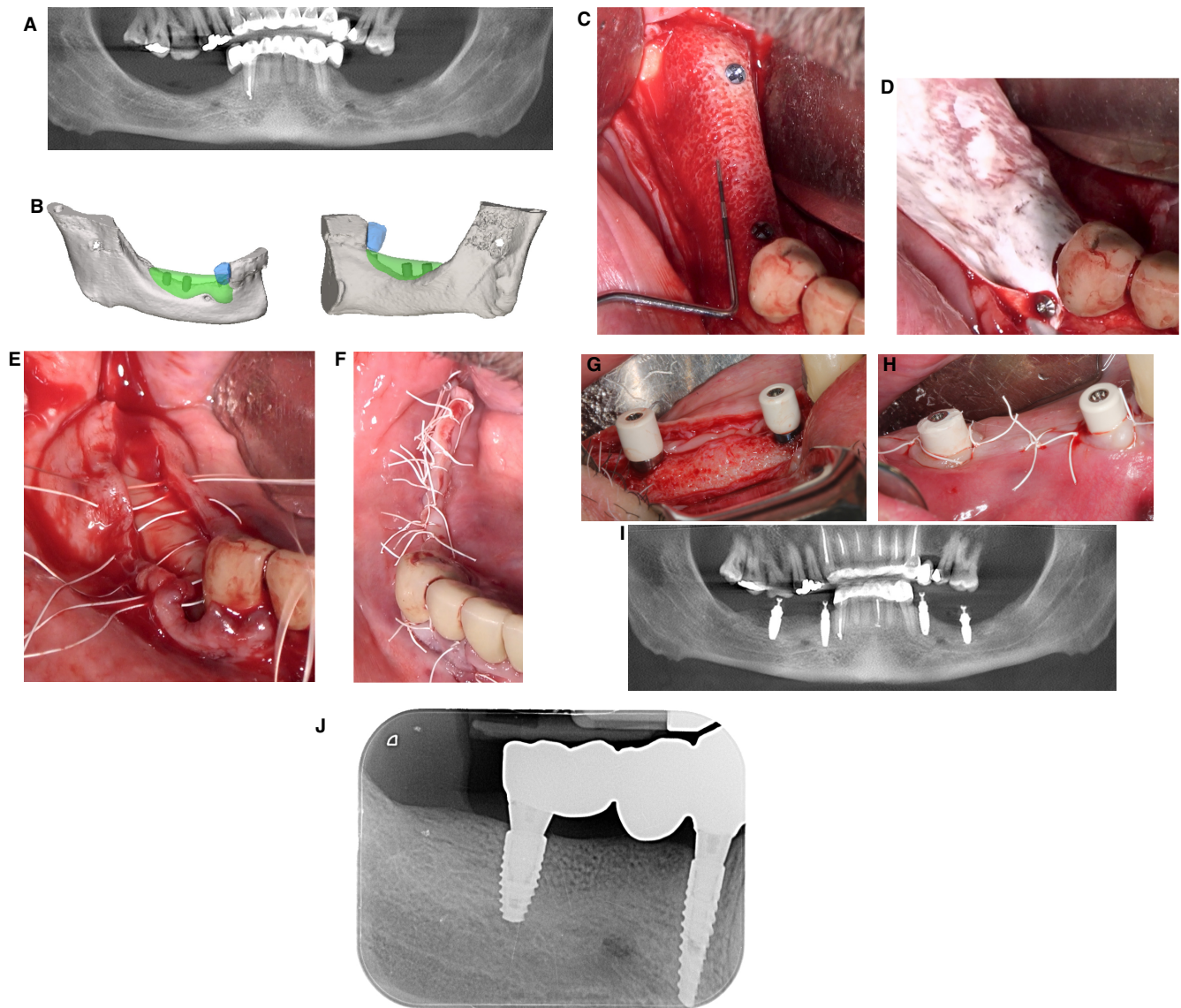


FIGURE 4 Representative case of the use of a computer-aided design/computer-aided manufacturing-customized allogenic bone graft. A, Patient presenting with bilateral vertical bone deficiencies in the posterior mandible. B, CAD of the allogenic bone blocks that will be placed in the affected areas. C and D, Intrasurgical view of the block placed after its fixation and covering with a native collagen membrane. E and F, Suturing of the surgical area with a combination of internal mattress sutures and single stitches. G–I, Implant placement in the ideal position 6 months later. J, Periapical radiograph of the implant-supported restoration 5 months after implant placement. Case kindly provided by Dr. Juan Blanco (University of Santiago de Compostela, Spain). computer-aided design/computer-aided manufacturing, computer-aided design/computer-aided manufacturing

Growth factors such as bone morphogenic proteins, platelet-derived growth factor, transforming growth factor-beta 1, insulin-like growth factor-1, and vascular endothelial growth factor have the ability of inducing the differentiation of stem cells into osteoblasts (ie, osteoinduction).⁸⁴ A wide range of results are reported regarding the use of growth factors in guided bone regeneration procedures, as they are frequently combined with different biomaterials and bone augmentation techniques, making it difficult to prove any superiority of their effect.^{51,85,86}

The use of transplanted cells to promote and direct wound healing is commonly named cell therapy. Cells, factors for tissue induction, and a matrix for seeding cells are the three key factors of this

technology. This combination has been proven to allow the growth of tissue in vitro, prior to implantation into the subject.⁸⁷

Stem cells can differentiate into a wide variety of cell types, including osteogenic cells. The bone marrow stroma contains hematopoietic and mesenchymal stem cells that have an important potential of differentiation,⁸⁸ being able to lead to bone formation in ectopic places.⁸⁹ Indeed, bone block allografts impregnated with bone marrow aspirated from the iliac crest have been presented as a predictable and effective treatment for deficient alveolar ridges compared with harvesting autogenous bone.⁹⁰ One of the various sources of mesenchymal stem cells is adipose tissue. For this reason, the buccal fat pad has been proposed as a suitable intra-oral

source of osteoprogenitor cells.⁹¹ Specifically, an exploratory clinical study performed in Iran included 14 patients with an atrophic posterior mandible who received buccal fat pad-derived stem cells with deproteinized bovine bone mineral as a scaffold for vertical ridge augmentation (test group) or a combination of deproteinized bovine bone mineral with particulated autogenous bone (control group).⁹² After 6 months, no differences in the quantitative analysis of cone beam computed tomography images for new bone formation were observed between the groups, showing that the bone formation of buccal fat pad stem cells is comparable with that of particulated autogenous bone when combined with deproteinized bovine bone mineral.

During the different steps of tissue engineering, the design of the scaffold prior to exposure to cells is of vital importance. The main characteristic of the scaffold is that it must present a surface that promotes cell attachment, growth, and differentiation, at the same time as providing a porous network for tissue growth. Three-dimensional printing has also been proposed to customize these scaffolds in the field of bone augmentation procedures.⁹³ The most commonly evaluated scaffolds for craniofacial bone regeneration include xenogenic, allogenic, and synthetic bone substitutes. However, limitations to their use are related to their lack of degradability or too quick degradability, as well as an inability to maintain the desired bone volume under mechanical stimuli. Ideally, these scaffolds should be degradable at a similar rate to that of bone tissue turnover, with large, interconnected pores allowing for cell incorporation, proliferation, and migration, etc. For this reason, future scaffolds will probably be synthetic (eg, different polymers) and able to be constructed using computer-aided design/computer-aided manufacturing technologies to adapt to bone defects with complex geometries.⁹⁴

Another possibility is three-dimensional bioprinting. This technology is based on the same principles of earlier three-dimensional printing technologies, but has been customized to manufacture permanent implants, biomimetic scaffolds and drug delivery platforms using cells, growth factors, and biomaterials as input materials. The technology can produce objects with controlled morphology and an internal structure that has a highly similar structure to the human body. Currently, the technology is used in various aspects of tissue engineering and regenerative medicine applications, including hard and soft tissue printing, cartilage printing, skin printing, and tumorous tissue model printing.⁹⁵ According to the comprehensive review by Ventola,⁴¹ the major steps in three-dimensional bioprinting include: (i) creating a blueprint of the desired organ with its vascular architecture; (ii) generating a bioprinting process plan; (iii) isolating stem cells and differentiating them into organ-specific cells; (iv) preparing bio-ink reservoirs with organ-specific cells, blood vessel cells, and a support medium to be loaded into the printer; (v) bioprinting the required product; and (vi) placing the bioprinted organ into a bioreactor prior to transplantation. With the development of this technology it is expected that we will have the opportunity to print customized synthetic bone enriched with growth factors and stem cells to reconstruct alveolar ridge defects.

Indeed, a proof-of-concept feasibility study was conducted at the University of Michigan to evaluate, in a randomized controlled trial, the effect of cell therapy with Ixmyelocel-T adsorbed into a gelatin sponge following the guided bone regeneration principles (test group) vs a guided bone regeneration group with the gelatin carrier alone (control group).⁹⁶ Histological analyses revealed that biopsy specimens from the test group presented a higher density of bone. However, it should be noted that these approaches are expensive and thus are currently limited to the research environment. Furthermore, they require harvesting a bone marrow sample from the iliac crest.

Another clinical study evaluated the potential of mesenchymal stem cells in a biphasic calcium phosphate scaffold in the reconstruction of large mandibular bone defects.⁹⁷ Non-resorbable dense polytetrafluoroethylene membranes were used to provide a tenting effect, while 5 cm³ of biphasic calcium phosphate mixed with 100 million mesenchymal cells was applied below the membrane. After 4-6 months of healing, the regenerated bone volume was adequate to place dental implants and healing was uneventful. It is expected that because of the disadvantages of autologous grafting, which is still the gold standard, future trends will be focused on the development of synthetic scaffolds enriched with stem cells and/or growth factors.

4 | COMPLICATIONS, SEQUELAE, AND MORBIDITY IN VERTICAL RIDGE AUGMENTATION

4.1 | Complications

Vertical ridge augmentation is a complex, technique-sensitive intervention, which entails a risk of short- and long-term complications.¹⁴

Short-term complications are the most documented, as they occur during the healing of the reconstructive procedure. These are mainly represented by flap dehiscence and infection of the underlying regenerative biomaterials, and have been described from 1 week up to 6 months after surgery.⁹⁸⁻¹⁰¹ In a recent systematic review on vertical ridge augmentation, their weighted mean incidence was 16.9%.⁵² Specifically, based on no direct comparison, distraction osteogenesis presented the highest rate (47.3%), followed by the use of bone blocks (23.9%) and guided bone regeneration (12.1%).⁵²

Among bone blocks, the highest weighted mean incidence of complication was observed with allografts (39.2%), while when using autogenous bone, the shell technique presented less frequent complications than onlay blocks (17.8% vs 26.1%). These included both wound infection with or without block exposure, incomplete block integration, and block mobilization at the time of implant placement.^{23,102} Because of the technical sensitivity of the procedure, a clear heterogeneity was observed among the different studies, with some reporting up to 77% with complications¹⁰³ and others reporting less than 10%^{16,104} or no complications.¹⁰⁵ While some cases of superficial exposure only required to remove the most coronal

portion of the graft,¹⁰⁶ others resulted in significant graft resorption with a need for additional grafting at the time of implant placement,¹⁰⁷ or in the complete loss of the block graft.¹⁰³

Interestingly, among guided bone regeneration techniques, complications were most frequent when using a resorbable (22.7%) vs nonresorbable membrane (6.9%), as was also described in previous systematic reviews.^{32,108,109} Such a finding may reflect the publication bias observed, specifically for the case series included in the aforementioned review, and could be explained by the fact that most of the reports are published by a selective group of master clinicians that presents outstanding results, but with limited external validity for other practitioners. Furthermore, it is expected that a higher degree of caution was taken studies applying nonresorbable membranes, as the management of wound dehiscences is more complex when using this type of barrier.

Indeed, to provide specific indications for the clinical management of healing complications with nonresorbable membranes, Fontana et al¹¹⁰ distinguished four classes of contingencies based on the extent of the wound dehiscence and the presence or absence of an underlying infection: (i) class 1: small membrane exposure (≤ 3 mm) without purulent exudate; (ii) class 2: large membrane exposure (> 3 mm) without purulent exudate; (iii) class 3: membrane exposure with purulent exudate; and (iv) class 4: abscess formation without membrane exposure.

Class 1 exposures, being the smallest, allow for an attempt to maintain the membrane in place for an additional month, under a strict plaque control regimen, supplemented by the use of local antiseptics. Such an indication is provided based on the *in vitro* evidence that bacterial penetration through expanded polytetrafluoroethylene membranes requires approximately 3-4 weeks, during which further maturation of the underlying grafting material can occur, before the membrane is removed.¹¹¹ Such time could potentially be increased when using dense polytetrafluoroethylene membranes, as a higher cell occlusivity has been described for this type of barrier.¹¹² Class 2 to class 4 cases, on the other hand, require the immediate removal of the membrane, with additional curettage of the infected bone particles in class 3 and class 4 cases.¹¹⁰

Exposure rates comparable with the ones for guided bone regeneration have also been reported with the use of titanium meshes combined with resorbable collagen membranes.^{22,29} Specifically, direct comparative data were provided by a randomized controlled trial conducted by Cucchi et al,²² who reported no significant differences in the incidence of healing complications when performing vertical ridge augmentation in the posterior mandible with dense polytetrafluoroethylene membranes (15.0%) vs noncustomized titanium meshes combined with crosslinked collagen membranes (21.1%). Similarly, a cohort study conducted by Chiapasco et al²⁹ reported an exposure incidence of 20.75% when performing vertical ridge augmentation with customized computer-aided design/computer-aided manufacturing titanium meshes combined with a native collagen membrane.

Long-term complications, on the other hand, are those which occur once the regenerated bone receives an implant-supported rehabilitation, and mainly comprise the onset of peri-implant diseases. Fewer data are available in this respect, as most studies on vertical ridge augmentation do not report the occurrence of biologic complications based on specific, unified, case definitions. Urban et al¹¹³ reported progressive bone loss of > 2 mm combined with bleeding on probing in 3.73% of implants in vertically augmented sites at 12-72 months after loading, while Merli et al¹¹⁴ reported that 0% of the implants had a progressive bone loss of > 3 mm combined with bleeding on probing 6 years after vertical ridge augmentation with guided bone regeneration.

Most studies reported either the occurrence of peri-implantitis without a specific case definition or based on the bone loss thresholds established by Albrektsson and Zarb¹¹⁵, with heterogenous data.^{8,16,116,117}

4.2 | Sequelae and morbidity of vertical ridge augmentation

Vertical ridge augmentation aims to reconstruct severely atrophic edentulous ridges where the residual bone volume does not allow the placement of dental implants in their optimal prosthetic position, even if adopting short or narrow implants.⁵²

Thus, its surgical invasiveness is related to two main factors: the involvement of delicate anatomic structures within the surgical site, and the amount of flap passivation required to achieve primary closure, which is proportionate to the volume of the grafted bone.¹¹⁸ Further invasiveness can derive from the harvest of autogenous bone grafts, which, based on the adopted reconstructive approach, can be performed locally, or at a second intra-oral or extraoral site.¹⁴

Involvement of local anatomic structures is a common event when performing vertical ridge augmentation in the posterior mandible, as the emergence of the mental nerve is frequently exposed during flap elevation, and a blunt dissection of its main branches is sometimes required to achieve proper flap passivation. Postoperative paresthesia of the mental nerve has been reported in 12%-27% of mandibular vertical ridge augmentation cases, albeit its resolution occurred spontaneously within a short timeframe.^{23,119,120}

Further anatomic structures that could be exposed during vertical ridge augmentation include the nasal floor,¹²¹ the maxillary sinus,¹²² the canal sinus,¹²³ and the inferior alveolar nerve when severe mandibular atrophies result in its superficialization in the edentulous crest.¹²⁴ Furthermore, flap passivation in the upper arch can result in the involvement of peripheral branches of the infraorbital nerve¹²⁵ and the buccal fat pad,¹²⁶ while in the lower arch it can expose the submandibular gland and Wharton duct, the mylohyoid muscle and artery,^{127,128} and the lingual nerve.¹²⁹ In order to avoid damage to such anatomic structures, the use of blunt dissection has been advocated during flap passivation, especially in the lingual aspect of the posterior mandible.^{130,131}

Extensive passivation and coronal advancement of the flaps results in postoperative edema and hematoma, which usually peaks within 48-72 hours, diffuses based on the position of muscle insertions, fascia, and bone structures, and then resolves in the following days.¹³²⁻¹³⁴ While the use of corticosteroids has been validated as an efficacious means with which to reduce swelling after the extraction of impacted third molars, some concerns have been raised with their use in bone reconstructive procedures, as a potential interfering effect of corticoids with the incorporation of bone grafts has been described in animal models.^{135,136}

Finally, postoperative sequelae associated with the harvesting of autogenous bone have been described for both intra-oral and extra-oral sites, especially with the harvesting of bone blocks. When focusing on intra-oral sites, the linea obliqua externa of the mandible is the most commonly adopted site from which to harvest autogenous bone (Clavero & Lundgren, 2003; Chiapasco et al. 2009)^{14,137}. When adopting a conventional harvesting technique with a combination of burs and micro saws, Khoury and Hanser³⁷ reported an incidence of minor alveolar nerve injuries (eg, hypoesthesia or paresthesia) in 20 out of 3874 cases (0.5%). Alternatively, the mandibular symphysis has been advocated as an accessible donor site, albeit that in the presence of the lower incisors altered sensitivity has been described in a significant percentage of cases. In the study conducted by Clavero and Lundgren,¹³⁷ permanent paresthesia in the mental region was observed in 51.7% of cases.

Independently of the site of harvesting, the adoption of modern technologies based on piezoelectric surgery and computer-aided design/computer-aided manufacturing guides for bone harvesting appears to be a promising approach to increase the accuracy of the block harvesting procedure and reduce the risk of complications.³⁹ Also, the use of bone scrapers has been advocated as a less invasive means to collect particulated autogenous bone compared with the harvesting and extraoral milling of bone blocks, allowing, in certain clinical scenarios, the collection of smaller bone quantities without the involvement of a second surgical site.¹³⁸ Interestingly, evidence from preclinical studies reported similar amounts of osteogenic cell DNA, cell adhesion, and proliferation rates in bone samples harvested with the two techniques, which were superior to the ones achieved with piezosurgery or a bone trap filter within an aspiration device.¹³⁹

5 | FACTORS INFLUENCING THE OUTCOMES OF VERTICAL RIDGE AUGMENTATION PROCEDURES (PATIENT AND SITE RISK FACTORS)

Vertical ridge augmentation has been regarded as a highly sensitive intervention, where the operator's technical skills, patient's risk profile, and site-specific features are pivotal to success. Patient-related risk factors seem to be common regardless of the type of intervention. A smoking habit has been suggested to limit the extent of vertical ridge augmentation,⁴ to lead to a higher risk of postoperative

complications,^{36,66} and to increase the rate of implant failure in regenerated bone.¹⁴⁰ The rationale behind this clinical observation is that smoking increases the number of osteoclasts by inhibiting osteoclast apoptosis via the mitochondrial reactive oxygen species and cytochrome C-caspase-3 pathway, also affecting bone marrow cells, leading to an increased formation of osteoclasts.¹⁴¹ It is encouraged, therefore, to restrict smoking for at least 3 months before vertical ridge augmentation.⁴ Moreover, other conditions affecting wound healing such as diabetes mellitus have been identified as detrimental factors for vertical ridge augmentation.⁶⁶ In these patients it must be noted, though, that appropriate metabolic control may reverse the adverse effect.⁶⁴ Therefore, a comprehensive anamnesis is crucial prior to vertical ridge augmentation to identify and modify potential patient-related risk factors that may compromise the primary outcome. Although these patient-related features may not affect the invasiveness of vertical ridge augmentation, it is critical to disclose them to understand the limitations of this procedure based upon the risk profile.

In addition, site-specific factors influencing vertical ridge augmentation outcomes have been identified in clinical studies and suggested in expert opinion reviews. These might be of interest to select minimally invasive approaches. For instance, it was proved that bone gain in the maxilla was significantly greater in the posterior compared with the anterior area (mean difference = 0.36 mm). On the other side, in the mandible, bone gain was greater in the anterior in contrast to the posterior area (mean difference = 0.32 mm).¹⁴² Furthermore, it was claimed that optimal results are anticipated in the presence of a concave defect topography neighbored by adjacent bony peaks instead of isolated supra-crestal defects, where attaining space creation is more arduous and demands higher expertise.^{4,143} The former scenarios might be more prone to succeed whenever minimally invasive approaches are applied. Along these lines, it is important to note that tension-free primary closure dictates the extent of achievable vertical ridge augmentation and the possibility of postoperative complications.¹⁴⁴ In this sense, it is paramount to conceive the nature of the periosteum and vestibular depth as critical factors to succeed in vertical ridge augmentation.^{145,146} To overcome scenarios like a damaged periosteum or shallow vestibule, technical maneuvers such as the remote/safety/vestibular shifted flap, the papilla shift approach, or periosteoplasty, have been recommended.^{49,145} The latter scenarios might be more challenging for the application of minimally invasive approaches.

6 | LONG-TERM OUTCOMES OF VERTICAL RIDGE AUGMENTATION PROCEDURES

Vertical ridge augmentation is a well-documented procedure with implant success and survival rates similar to those placed in native bone.^{108,147} However, only few studies have reported the long-term marginal bone level changes around implants placed on vertically augmented sites.^{16,52,104} In this context, a recent systematic review identified only 11 investigations evaluating bone level changes at

least 12 months after loading. Among these studies, most of them reported marginal bone level changes similar to those around implants placed into native bone. On the contrary, three studies showed that 5.8%-20% of the implants placed in vertically augmented sites had bone loss above the criteria defined by Albrektsson and Zarb.^{8,116,117}

An important factor to be considered is the timing of bone remodeling, because it should be noted that in some cases after vertical ridge augmentation there might be more bone loss during the adaptation phase. As an example, Simion et al¹⁴⁸ conducted a retrospective study reporting on implants with a machined surface 13-21 years after loading. It was found that between the first year and the final visit, minimal marginal bone loss occurred (1.02mm), demonstrating a stability of the crestal bone similar to native bone. However, it must be highlighted that the baseline radiographs were taken 1 year after physiological bone remodeling, when bone levels were already located 2.11mm below the implant shoulder of Branemark implants. These results suggest that we cannot take for granted that there will be no bone loss around implants placed into vertically augmented bone and that external hexagon designs may be associated with greater initial bone remodeling.^{148,149} In this context, implant design and surface characteristics may play a role. To prevent biologic complications because of the exposure of the rough surface secondary to bone loss, the use of one-piece implant designs (such as tissue level implants), hybrid implant surfaces, and the sub-crestal placement of implants have been proposed.¹⁵⁰⁻¹⁵⁵

To minimize the initial bone remodeling associated with vertical ridge augmentation procedures, a second protecting layer of bone grafting at the time of implant placement has also been advocated.¹⁴⁶ Results using a mixture of a slowly resorbable xenogenic bone graft and autogenous bone chips covered with a resorbable membrane demonstrated that epi-crestally placed implants into vertically augmented bone exhibited excellent marginal bone stability.¹⁵⁶ Increasing of the soft tissue thickness has also been proposed to prevent marginal bone loss, because vertical ridge augmentation procedures may result in stretching and thinning of the soft tissues during regenerative surgeries.^{51,157} Additionally, many patients have minimal or no keratinized tissues at the end of regenerative therapy, which has been identified as one important factor impairing oral hygiene and increasing the risk of biologic complications. Therefore, soft tissue grafting to increase keratinized tissue should be frequently considered after vertical ridge augmentation procedures.⁵¹ In two long-term retrospective studies,^{16,104} in which patients presenting with edentulous and atrophic ridges were treated with autogenous mandibular or calvarial bone blocks and were rehabilitated with implant-supported prostheses, the use of vestibuloplasty in association with free gingival grafts reduced the incidence of implant failures and peri-implantitis, although the difference was not statistically significant. Nevertheless, these techniques as well as the aforementioned factors should be investigated in well-designed randomized clinical trials.

Outcomes associated with peri-implant health or disease, such as mucosal or bleeding indexes, as well as probing depths, have been reported rarely and inconsistently in studies dealing with vertical

ridge augmentation.⁵² This fact, together with the scarcity of long-term reports, hinders having a clear image of the incidence of biologic complications of implants placed into vertically augmented sites using different surgical approaches. Moreover, several factors, such as the previous history of periodontitis, can influence long-term results. Rocuzzo et al,¹⁵⁸ in a long-term clinical study analyzing periodontal indexes and Marginal bone levels around nonsubmerged implants placed after vertical alveolar ridge augmentation, reported statistically significant greater bone loss in patients whose bone atrophy was the consequence of a previous history of periodontitis. Therefore, primary prevention protocols are still the main tool to assure the long-term stability of implants placed in this clinical scenario. Proper maintenance protocols and oral hygiene strategies should be developed and individualized for each patient.^{159,160}

7 | SUMMARY AND CONCLUSIONS

Vertical ridge augmentation is a challenging procedure that aims to reconstruct the alveolar process in situations where no osseous wall containment is present, and therefore it is questionable if it should be considered minimally invasive. However, this does not mean that new advances have not been developed to simplify the procedure, making it easier for clinicians and, consequently, having an impact on a patient's morbidity (even if patient-reported outcome measures have not been properly evaluated in most of the reports).

Among the most relevant innovations, advances in preoperative treatment planning together with digital tools such as computer-aided design/computer-aided manufacturing technologies have allowed customizing titanium meshes or bone/bone substitute blocks (eg, computer-guided bone harvesting procedures, three-dimensional-printed bone models to preshape meshes or allograft plates, three-dimensional-printed allogenic/xenogenic/alloplastic bone blocks, digitalization and customization of reinforced polytetrafluoroethylene meshes, etc.), reducing treatment time and restoring geometrically complex anatomic defects with accuracy and precision. Furthermore, the use of biomaterials instead of autogenous onlay blocks (which are still the gold standard) reduces the need for a donor site and the potential complications associated with a second surgical site. However, the truth is that these approaches have been presented in only a few short-term case reports, and it remains questionable what are the most suitable biomaterials, their resorption rate, or the long-term results of the implants placed in these augmented ridges.

Different surgical designs have also been proposed to reduce the invasiveness and risk of complications in ridge augmentation procedures, including tunnel techniques, different periosteal releasing incisions, apical accesses, and the absence of vertical releasing incisions, etc. Unfortunately, these techniques have been described mostly in retrospective case series, and their efficacy have not been tested in properly designed randomized clinical trials, including the evaluation of patient-reported outcome measures.

Probable future trends in vertical ridge augmentation will rely on new strategies in regenerative medicine and tissue engineering

using stem cells on three-dimensional-printed scaffolds. However, their use is currently limited to research environments because of costs and legislation, and it is crucial that they provide additional benefits over current standard therapies (ie, guided bone regeneration, the shell technique with autogenous bone).

ACKNOWLEDGMENTS

The authors want to thank Prof. Dr. Juan Blanco, from the University of Santiago de Compostela (Spain), for providing us with the case presented as Figure 4.

FUNDING INFORMATION

This manuscript was self-funded.

CONFLICT OF INTEREST

All authors declare no conflict of interest.

DATA AVAILABILITY STATEMENT

Data sharing not applicable to this article as no datasets were generated or analysed during the current study.

ORCID

Alberto Monje  <https://orcid.org/0000-0001-8292-1927>

REFERENCES

- Harrel SK. A minimally invasive surgical approach for periodontal bone grafting. *Int J Periodontics Restorative Dent*. 1998;18(2):161-169.
- Harrel SK. Videoscope-assisted minimally invasive surgery (VMIS) for bone regeneration around teeth and implants: a literature review and technique update. *Dent J (Basel)*. 2018;6(3):30.
- Assael LA. Minimally invasive oral and maxillofacial surgery: rational advancement of technology. *J Oral Maxillofac Surg*. 2003;61(10):1121-1122.
- Urban IA, Monje A. Guided bone regeneration in alveolar bone reconstruction. *Oral Maxillofac Surg Clin North Am*. 2019;31(2):331-338.
- Ravida A, Barootchi S, Tattan M, Saleh MHA, Gargallo-Albiol J, Wang HL. Clinical outcomes and cost effectiveness of computer-guided versus conventional implant-retained hybrid prostheses: a long-term retrospective analysis of treatment protocols. *J Periodontol*. 2018;89(9):1015-1024.
- Papaspyridakos P, De Souza A, Vazouras K, Gholami H, Pagni S, Weber HP. Survival rates of short dental implants ($\leq 6\text{ mm}$) compared with implants longer than 6 mm in posterior jaw areas: a meta-analysis. *Clin Oral Implants Res*. 2018;29(Suppl 16):8-20.
- Vazouras K, de Souza AB, Gholami H, Papaspyridakos P, Pagni S, Weber HP. Effect of time in function on the predictability of short dental implants ($\leq 6\text{ mm}$): a meta-analysis. *J Oral Rehabil*. 2020;47(3):403-415.
- Chiapasco M, Consolo U, Bianchi A, Ronchi P. Alveolar distraction osteogenesis for the correction of vertically deficient edentulous ridges: a multicenter prospective study on humans. *Int J Oral Maxillofac Implants*. 2004;19(3):399-407.
- Chin M, Toth BA. Distraction osteogenesis in maxillofacial surgery using internal devices: review of five cases. *J Oral Maxillofac Surg*. 1996;54(1):45-53. discussion 54.
- Jensen OT, Ringeman JL, Cottam JR, Casap N. Orthognathic and osteoperiosteal flap augmentation strategies for maxillary dental implant reconstruction. *Oral Maxillofac Surg Clin North Am*. 2011;23(2):301-319. vi.
- Pjetursson BE, Tan WC, Zwahlen M, Lang NP. A systematic review of the success of sinus floor elevation and survival of implants inserted in combination with sinus floor elevation. *J Clin Periodontol*. 2008;35(8 Suppl):216-240.
- Pjetursson BE, Igrnjatic D, Matuliene G, Bragger U, Schmidlin K, Lang NP. Transalveolar maxillary sinus floor elevation using osteotomes with or without grafting material. Part II: radiographic tissue remodeling. *Clin Oral Implants Res*. 2009;20(7):677-683.
- Chiapasco M, Brusati R, Ronchi P. Le fort I osteotomy with interpositional bone grafts and delayed oral implants for the rehabilitation of extremely atrophied maxillae: a 1-9-year clinical follow-up study on humans. *Clin Oral Implants Res*. 2007;18(1):74-85.
- Chiapasco M, Casentini P, Zaniboni M. Bone augmentation procedures in implant dentistry. *Int J Oral Maxillofac Implants*. 2009;24(Suppl):237-259.
- Chiapasco M, Casentini P. Horizontal bone-augmentation procedures in implant dentistry: prosthetically guided regeneration. *Periodontol 2000*. 2018;77(1):213-240.
- Chiapasco M, Tommasato G, Palombo D, Del Fabbro M. A retrospective 10-year mean follow-up of implants placed in ridges grafted using autogenous mandibular blocks covered with bovine bone mineral and collagen membrane. *Clin Oral Implants Res*. 2020;31(4):328-340.
- Esposito M, Grusovin MG, Felice P, Karatzopoulos G, Worthington HV, Coulthard P. The efficacy of horizontal and vertical bone augmentation procedures for dental implants – a Cochrane systematic review. *Eur J Oral Implantol*. 2009;2(3):167-184.
- Nkenke E, Neukam FW. Autogenous bone harvesting and grafting in advanced jaw resorption: morbidity, resorption and implant survival. *Eur J Oral Implantol*. 2014;7(Suppl 2):S203-S217.
- Schwartz-Arad D, Ofec R, Eliyahu G, Ruban A, Sterer N. Long term follow-up of dental implants placed in autologous Onlay bone graft. *Clin Implant Dent Relat Res*. 2016;18(3):449-461.
- Smolka W. Calvarial grafts for alveolar ridge reconstruction prior to dental implant placement: an update. *Oral Maxillofac Surg*. 2014;18(4):381-385.
- von Arx T, Buser D. Horizontal ridge augmentation using autogenous block grafts and the guided bone regeneration technique with collagen membranes: a clinical study with 42 patients. *Clin Oral Implants Res*. 2006;17(4):359-366.
- Cucchi A, Vignudelli E, Napolitano A, Marchetti C, Corinaldesi G. Evaluation of complication rates and vertical bone gain after guided bone regeneration with non-resorbable membranes versus titanium meshes and resorbable membranes. A randomized clinical trial. *Clin Implant Dent Relat Res*. 2017;19(5):821-832.
- Rocuzzo M, Ramieri G, Bunino M, Berrone S. Autogenous bone graft alone or associated with titanium mesh for vertical alveolar ridge augmentation: a controlled clinical trial. *Clin Oral Implants Res*. 2007;18(3):286-294.
- Her S, Kang T, Fien MJ. Titanium mesh as an alternative to a membrane for ridge augmentation. *J Oral Maxillofac Surg*. 2012;70(4):803-810.
- Miyamoto I, Funaki K, Yamauchi K, Kodama T, Takahashi T. Alveolar ridge reconstruction with titanium mesh and autogenous particulate bone graft: computed tomography-based evaluations of augmented bone quality and quantity. *Clin Implant Dent Relat Res*. 2012;14(2):304-311.
- Briguglio F, Falcomata D, Marconcini S, Fiorillo L, Briguglio R, Farronato D. The use of titanium mesh in guided bone regeneration: a systematic review. *Int J Dent*. 2019;2019:9065423.
- Sumida T, Otawa N, Kamata YU, et al. Custom-made titanium devices as membranes for bone augmentation in implant treatment: clinical application and the comparison with conventional titanium mesh. *J Craniomaxillofac Surg*. 2015;43(10):2183-2188.
- Sagheb K, Schiegnitz E, Moergel M, Walter C, Al-Nawas B, Wagner W. Clinical outcome of alveolar ridge augmentation with

- individualized CAD-CAM-produced titanium mesh. *Int J Implant Dent.* 2017;3(1):36.
29. Chiapasco M, Casentini P, Tommasato G, Dellavia C, Del Fabbro M. Customized CAD/CAM titanium meshes for the guided bone regeneration of severe alveolar ridge defects: preliminary results of a retrospective clinical study in humans. *Clin Oral Implants Res.* 2021;32(4):498-510.
 30. Cucchi A, Bianchi A, Calamai P, et al. Clinical and volumetric outcomes after vertical ridge augmentation using computer-aided-design/computer-aided manufacturing (CAD/CAM) customized titanium meshes: a pilot study. *BMC Oral Health.* 2020;20(1):219.
 31. Plonka AB, Urban IA, Wang HL. Decision tree for vertical ridge augmentation. *Int J Periodontics Restorative Dent.* 2018;38(2):269-275.
 32. Milinkovic I, Cordaro L. Are there specific indications for the different alveolar bone augmentation procedures for implant placement? A systematic review. *Int J Oral Maxillofac Surg.* 2014;43(5):606-625.
 33. von See C, Gellrich NC, Bormann KH, Rahmann A, Rucker M. Microvascular response to the subperiosteal implantation of self-inflating hydrogel expanders. *Int J Oral Maxillofac Implants.* 2010;25(5):979-984.
 34. von See C, Gellrich NC, Jachmann U, Laschke MW, Bormann KH, Rucker M. Bone augmentation after soft-tissue expansion using hydrogel expanders: effects on microcirculation and osseointegration. *Clin Oral Implants Res.* 2010;21(8):842-847.
 35. Morad G, Khojasteh A. Cortical tenting technique versus onlay layered technique for vertical augmentation of atrophic posterior mandibles: a split-mouth pilot study. *Implant Dent.* 2013;22(6):566-571.
 36. Khoury F, Hanser T. Three-dimensional vertical alveolar ridge augmentation in the posterior maxilla: a 10-year clinical study. *Int J Oral Maxillofac Implants.* 2019;34(2):471-480.
 37. Khoury F, Hanser T. Mandibular bone block harvesting from the retromolar region: a 10-year prospective clinical study. *Int J Oral Maxillofac Implants.* 2015;30(3):688-697.
 38. De Stavola L, Tunkel J. Results of vertical bone augmentation with autogenous bone block grafts and the tunnel technique: a clinical prospective study of 10 consecutively treated patients. *Int J Periodontics Restorative Dent.* 2013;33(5):651-659.
 39. De Stavola L, Fincato A, Bressan E, Gobato L. Results of computer-guided bone block harvesting from the mandible: a case series. *Int J Periodontics Restorative Dent.* 2017;37(1):e111-e119.
 40. Jacotti M. Simplified onlay grafting with a 3-dimensional block technique: a technical note. *Int J Oral Maxillofac Implants.* 2006;21(4):635-639.
 41. Ventola CL. Medical applications for 3D printing: current and projected uses. *P T.* 2014;39(10):704-711.
 42. Venet L, Perriat M, Mangano FG, Fortin T. Horizontal ridge reconstruction of the anterior maxilla using customized allogeneic bone blocks with a minimally invasive technique - a case series. *BMC Oral Health.* 2017;17(1):146.
 43. Mangano FG, Zecca PA, van Noort R, et al. Custom-made computer-aided-design/computer-aided-manufacturing biphasic calcium-phosphate scaffold for augmentation of an atrophic mandibular anterior ridge. *Case Rep Dent.* 2015;2015:941265.
 44. Mirković S, Budak I, Puskar T, et al. Application of modern computer-aided technologies in the production of individual bone graft: a case report. *Vojnosanit Pregl.* 2015;72(12):1126-1131.
 45. Nilius M, Mueller C, Nilius MH, Haim D, Weiland B, Lauer G. Advanced backward planning with custom-milled individual allogeneic block augmentation for maxillary full-arch osteoplasty and dental implantation: a 3-year follow-up. *Cell Tissue Bank.* 2021.
 46. Li S, Zhang T, Zhou M, Zhang X, Gao Y, Cai X. A novel digital and visualized guided bone regeneration procedure and digital precise bone augmentation: a case series. *Clin Implant Dent Relat Res.* 2021;23(1):19-30.
 47. Ogata Y, Griffin TJ, Ko AC, Hur Y. Comparison of double-flap incision to periosteal releasing incision for flap advancement: a prospective clinical trial. *Int J Oral Maxillofac Implants.* 2013;28(2):597-604.
 48. Windisch P, Orban K, Salvi GE, Sculean A, Molnar B. Vertical-guided bone regeneration with a titanium-reinforced d-PTFE membrane utilizing a novel split-thickness flap design: a prospective case series. *Clin Oral Investig.* 2021;25(5):2969-2980.
 49. De Stavola L, Tunkel J, Fincato A, Fistarol F. The vestibular shifted flap Design for Vertical Bone Augmentation in the maxilla: case report and technical notes. *Int J Periodontics Restorative Dent.* 2021;41(3):367-373.
 50. Pagni G, Kaigler D, Rasperini G, Avila-Ortiz G, Bartel R, Giannobile WV. Bone repair cells for craniofacial regeneration. *Adv Drug Deliv Rev.* 2012;64(12):1310-1319.
 51. Tavelli L, Ravidá A, Barootchi S, Chambrone L, Giannobile WV. Recombinant human platelet-derived growth factor: a systematic review of clinical findings in Oral regenerative procedures. *JDR Clin Trans Res.* 2021;6(2):161-173.
 52. Urban IA, Montero E, Monje A, Sanz-Sanchez I. Effectiveness of vertical ridge augmentation interventions: a systematic review and meta-analysis. *J Clin Periodontol.* 2019;46(Suppl 21):319-339.
 53. Kumar KA, Masrom AK, Patil K, Kunusoth R, Begum F, Venkatesh V. Evaluation of vertical bone gain following alveolar distraction osteogenesis in the anterior edentulous mandible: a clinical study. *J Maxillofac Oral Surg.* 2014;13(4):539-545.
 54. Pisoni L, Lucchi A, Persia M, Marchi O, Ordesi P, Siervo S. Sinus lift: 3years follow up comparing autogenous bone block versus autogenous particulated grafts. *J Dent Sci.* 2016;11(3):231-237.
 55. de Azevedo RA, Matos FS, Figueiredo LMG. Appositional bone graft tunneled: technical note. *Int J Surg Case Rep.* 2017;33:143-147.
 56. Chiapasco M, Zaniboni M, Boisco M. Augmentation procedures for the rehabilitation of deficient edentulous ridges with oral implants. *Clin Oral Implants Res.* 2006;17(Suppl 2):136-159.
 57. Rios HF, Borgnakke WS, Benavides E. The use of cone-beam computed tomography in Management of Patients Requiring Dental Implants: an American Academy of periodontology best evidence review. *J Periodontol.* 2017;88(10):946-959.
 58. Buser D, Sennerby L, De Bruyn H. Modern implant dentistry based on osseointegration: 50 years of progress, current trends and open questions. *Periodontol 2000.* 2017;73(1):7-21.
 59. Sanz-Sanchez I, Sanz-Martin I, Ortiz-Vigón A, Molina A, Sanz M. Complications in bone-grafting procedures: classification and management. *Periodontol 2000.* 2022;88(1):86-102.
 60. Sakkas A, Schramm A, Winter K, Wilde F. Risk factors for post-operative complications after procedures for autologous bone augmentation from different donor sites. *J Craniomaxillofac Surg.* 2018;46(2):312-322.
 61. Levin L, Herzberg R, Dolev E, Schwartz-Arad D. Smoking and complications of onlay bone grafts and sinus lift operations. *Int J Oral Maxillofac Implants.* 2004;19(3):369-373.
 62. Strietzel FP, Reichart PA, Kale A, Kulkarni M, Wegner B, Kuchler I. Smoking interferes with the prognosis of dental implant treatment: a systematic review and meta-analysis. *J Clin Periodontol.* 2007;34(6):523-544.
 63. Retzeppi M, Donos N. The effect of diabetes mellitus on osseous healing. *Clin Oral Implants Res.* 2010;21(7):673-681.
 64. Retzeppi M, Lewis MP, Donos N. Effect of diabetes and metabolic control on de novo bone formation following guided bone regeneration. *Clin Oral Implants Res.* 2010;21(1):71-79.
 65. Farzad P, Andersson L, Nyberg J. Dental implant treatment in diabetic patients. *Implant Dent.* 2002;11(3):262-267.
 66. Schwartz-Arad D, Levin L, Sigal L. Surgical success of intraoral autogenous block onlay bone grafting for alveolar ridge augmentation. *Implant Dent.* 2005;14(2):131-138.

67. Plonka AB, Sheridan RA, Wang HL. Flap designs for flap advancement during implant therapy: a systematic review. *Implant Dent*. 2017;26(1):145-152.
68. Rocchietta I, Fontana F, Simion M. Clinical outcomes of vertical bone augmentation to enable dental implant placement: a systematic review. *J Clin Periodontol*. 2008;35(8 Suppl):203-215.
69. Windisch P, Martin A, Shahbazi A, Molnar B. Reconstruction of horizontoververtical alveolar defects. Presentation of a novel split-thickness flap design for guided bone regeneration: a case report with 5-year follow-up. *Quintessence Int*. 2017;48(7):535-547.
70. Mertens C, Thiele O, Engel M, Seeberger R, Hoffmann J, Freier K. The use of self-inflating soft tissue expanders prior to bone augmentation of atrophied alveolar ridges. *Clin Implant Dent Relat Res*. 2015;17(1):44-51.
71. Daga D, Mehrotra D, Mohammad S, Chandra S, Singh G, Mehrotra D. Tentpole technique for bone regeneration in vertically deficient alveolar ridges: a prospective study. *J Oral Biol Craniofac Res*. 2018;8(1):20-24.
72. Abrahamsson P, Isaksson S, Gordh M, Andersson G. Onlay bone grafting of the mandible after periosteal expansion with an osmotic tissue expander: an experimental study in rabbits. *Clin Oral Implants Res*. 2010;21(12):1404-1410.
73. Byun SH, Kim SY, Lee H, et al. Soft tissue expander for vertically atrophied alveolar ridges: prospective, multicenter, randomized controlled trial. *Clin Oral Implants Res*. 2020;31(7):585-594.
74. Navarro Cuéllar C, Tousidonis Rial M, Antúnez-Conde R, et al. Virtual surgical planning, Stereolithographic models and CAD/CAM titanium mesh for three-dimensional reconstruction of fibula flap with iliac crest graft and dental implants. *J Clin Med*. 2021;10(9):1922.
75. Beretta M, Poli PP, Maiorana C. Accuracy of computer-aided template-guided oral implant placement: a prospective clinical study. *J Periodontal Implant Sci*. 2014;44(4):184-193.
76. Baruffaldi A, Poli PP, Baruffaldi A, Giberti L, Pigozzo M, Maiorana C. Computer-aided flapless implant surgery and immediate loading. A technical note. *Oral Maxillofac Surg*. 2016;20(3):313-319.
77. Poli PP, Mukhtadar AK, Souza F, Maiorana C, Beretta M. Computer-guided implant placement associated with computer-aided bone regeneration in the treatment of atrophied partially edentulous alveolar ridges: a proof-of-concept study. *J Dent Sci*. 2021;16(1):333-341.
78. Hofferber CE, Beck JC, Liacouras PC, Wessel JR, Getka TP. Volumetric changes in edentulous alveolar ridge sites utilizing guided bone regeneration and a custom titanium ridge augmentation matrix (CTRAM): a case series study. *Int J Implant Dent*. 2020;6(1):83.
79. Mounir M, Shalash M, Mounir S, Nassar Y, El Khatib O. Assessment of three dimensional bone augmentation of severely atrophied maxillary alveolar ridges using prebent titanium mesh vs customized poly-ether-ether-ketone (PEEK) mesh: a randomized clinical trial. *Clin Implant Dent Relat Res*. 2019;21(5):960-967.
80. Honigmann P, Sharma N, Okolo B, Popp U, Msallem B, Thieringer FM. Patient-specific surgical implants made of 3D printed PEEK: material, technology, and scope of surgical application. *Biomed Res Int*. 2018;2018:4520636.
81. Draenert FG, Gebhart F, Mitov G, Neff A. Biomaterial shell bending with 3D-printed templates in vertical and alveolar ridge augmentation: a technical note. *Oral Surg Oral Med Oral Pathol Oral Radiol*. 2017;123(6):651-660.
82. Tunkel J, de Stavola L, Kloss-Brandstätter A. Alveolar ridge augmentation using the shell technique with allogeneic and autogenous bone plates in a split-mouth design—a retrospective case report from five patients. *Clin Case Rep*. 2021;9(2):947-959.
83. Yen HH, Stathopoulou PG. CAD/CAM and 3D-printing applications for alveolar ridge augmentation. *Curr Oral Health Rep*. 2018;5(2):127-132.
84. Giannobile WV. Periodontal tissue engineering by growth factors. *Bone*. 1996;19(1 Suppl):23S-37S.
85. Strauss FJ, Stahl A, Gruber R. The use of platelet-rich fibrin to enhance the outcomes of implant therapy: a systematic review. *Clin Oral Implants Res*. 2018;29(Suppl 18):6-19.
86. Stahl A, Strauss FJ, Gruber R. The use of platelet-rich plasma to enhance the outcomes of implant therapy: a systematic review. *Clin Oral Implants Res*. 2018;29(Suppl 18):20-36.
87. Vacanti JP, Langer R. Tissue engineering: the design and fabrication of living replacement devices for surgical reconstruction and transplantation. *Lancet*. 1999;354(Suppl 1):Si32-Si34.
88. Owen P, Connaghan DG, Holland HK, Steis RG. Bone marrow transplantation: cancer therapy comes of age. *J Med Assoc Ga*. 1998;87(2):145-146. 148.
89. Cooper LF, Harris CT, Bruder SP, Kowalski R, Kadiyala S. Incipient analysis of mesenchymal stem-cell-derived osteogenesis. *J Dent Res*. 2001;80(1):314-320.
90. Soltan M, Smiler D, Prasad HS, Rohrer MD. Bone block allograft impregnated with bone marrow aspirate. *Implant Dent*. 2007;16(4):329-339.
91. Farre-Guasch E, Marti-Page C, Hernandez-Alfaro F, Klein-Nulend J, Casals N. Buccal fat pad, an oral access source of human adipose stem cells with potential for osteochondral tissue engineering: an in vitro study. *Tissue Eng Part C Methods*. 2010;16(5):1083-1094.
92. Wychowski P, Woliński J, Morawiec T, et al. Preliminary clinical data and the comparison of the safety and efficacy of autogenous bone grafts versus xenograft implantations in vertical bone deficiencies before dental implant installation. *Transplant Proc*. 2020;52(7):2248-2251.
93. O'Brien CM, Holmes B, Faucett S, Zhang LG. Three-dimensional printing of nanomaterial scaffolds for complex tissue regeneration. *Tissue Eng Part B Rev*. 2015;21(1):103-114.
94. Ma PX. Biomimetic materials for tissue engineering. *Adv Drug Deliv Rev*. 2008;60(2):184-198.
95. Ozbolat IT, Peng W, Ozbolat V. Application areas of 3D bioprinting. *Drug Discov Today*. 2016;21(8):1257-1271.
96. Kaigler D, Pagni G, Park CH, Tarle SA, Bartel RL, Giannobile WV. Angiogenic and osteogenic potential of bone repair cells for craniofacial regeneration. *Tissue Eng Part A*. 2010;16(9):2809-2820.
97. Gjerde C, Mustafa K, Hellem S, et al. Cell therapy induced regeneration of severely atrophied mandibular bone in a clinical trial. *Stem Cell Res Ther*. 2018;9(1):213.
98. Buser D, Bragger U, Lang NP, Nyman S. Regeneration and enlargement of jaw bone using guided tissue regeneration. *Clin Oral Implants Res*. 1990;1(1):22-32.
99. Merli M, Migani M, Bernardelli F, Esposito M. Vertical bone augmentation with dental implant placement: efficacy and complications associated with 2 different techniques. A retrospective cohort study. *Int J Oral Maxillofac Implants*. 2006;21(4):600-606.
100. Merli M, Migani M, Esposito M. Vertical ridge augmentation with autogenous bone grafts: resorbable barriers supported by osteosynthesis plates versus titanium-reinforced barriers. A preliminary report of a blinded, randomized controlled clinical trial. *Int J Oral Maxillofac Implants*. 2007;22(3):373-382.
101. Poli PP, Beretta M, Cicciu M, Maiorana C. Alveolar ridge augmentation with titanium mesh. A retrospective clinical study. *Open Dent J*. 2014;8:148-158.
102. Rocchietta I, Simion M, Hoffmann M, Trisciuglio D, Benigni M, Dahlin C. Vertical bone augmentation with an autogenous block or particles in combination with guided bone regeneration: a clinical and histological preliminary study in humans. *Clin Implant Dent Relat Res*. 2016;18(1):19-29.
103. Leong DJ, Oh TJ, Benavides E, Al-Hezaimi K, Misch CE, Wang HL. Comparison between sandwich bone augmentation and allogenic

- block graft for vertical ridge augmentation in the posterior mandible. *Implant Dent.* 2015;24(1):4-12.
104. Chiapasco M, Tommasato G, Palombo D, Scarno D, Zaniboni M, Del Fabbro M. Dental implants placed in severely atrophic jaws reconstructed with autogenous calvarium, bovine bone mineral, and collagen membranes: a 3- to 19-year retrospective follow-up study. *Clin Oral Implants Res.* 2018;29(7):725-740.
 105. Abrahamsson P, Walivaara DA, Isaksson S, Andersson G. Periosteal expansion before local bone reconstruction using a new technique for measuring soft tissue profile stability: a clinical study. *J Oral Maxillofac Surg.* 2012;70(10):e521-e530.
 106. Mangano F, Macchi A, Shibli JA, et al. Maxillary ridge augmentation with custom-made CAD/CAM scaffolds. A 1-year prospective study on 10 patients. *J Oral Implantol.* 2014;40(5):561-569.
 107. Yu H, Chen L, Zhu Y, Qiu L. Bilamina cortical tenting grafting technique for three-dimensional reconstruction of severely atrophic alveolar ridges in anterior maxillae: a 6-year prospective study. *J Craniomaxillofac Surg.* 2016;44(7):868-875.
 108. Elnayef B, Monje A, Gargallo-Albiol J, Galindo-Moreno P, Wang HL, Hernandez-Alfaro F. Vertical ridge augmentation in the atrophic mandible: a systematic review and meta-analysis. *Int J Oral Maxillofac Implants.* 2017;32(2):291-312.
 109. Lim G, Lin GH, Monje A, Chan HL, Wang HL. Wound healing complications following guided bone regeneration for ridge augmentation: a systematic review and meta-analysis. *Int J Oral Maxillofac Implants.* 2018;33(1):41-50.
 110. Fontana F, Maschera E, Rocchietta I, Simion M. Clinical classification of complications in guided bone regeneration procedures by means of a nonresorbable membrane. *Int J Periodontics Restorative Dent.* 2011;31(3):265-273.
 111. Simion M, Baldoni M, Rossi P, Zaffe D. A comparative study of the effectiveness of e-PTFE membranes with and without early exposure during the healing period. *Int J Periodontics Restorative Dent.* 1994;14(2):166-180.
 112. De Sanctis M, Zucchelli G, Clauser C. Bacterial colonization of barrier material and periodontal regeneration. *J Clin Periodontol.* 1996;23(11):1039-1046.
 113. Urban IA, Monje A, Lozada JL, Wang HL. Long-term evaluation of peri-implant bone level after reconstruction of severely atrophic edentulous maxilla via vertical and horizontal guided bone regeneration in combination with sinus augmentation: A case series with 1 to 15 years of loading. *Clin Implant Dent Relat Res.* 2017;19(1):46-55.
 114. Merli M, Moscatelli M, Mariotti G, Rotundo R, Bernardelli F, Nieri M. Bone level variation after vertical ridge augmentation: resorbable barriers versus titanium-reinforced barriers. A 6-year double-blind randomized clinical trial. *Int J Oral Maxillofac Implants.* 2014;29(4):905-913.
 115. Albrektsson T, Zarb G, Worthington P, Eriksson AR. The long-term efficacy of currently used dental implants: a review and proposed criteria for success. *Int J Oral Maxillofac Implants.* 1986;1(1):1.
 116. Fontana F, Grossi GB, Fimano M, Maiorana C. Osseointegrated implants in vertical ridge augmentation with a nonresorbable membrane: a retrospective study of 75 implants with 1 to 6 years of follow-up. *Int J Periodontics Restorative Dent.* 2015;35(1):29-39.
 117. Llambes F, Silvestre FJ, Caffesse R. Vertical guided bone regeneration with bioabsorbable barriers. *J Periodontol.* 2007;78(10):2036-2042.
 118. Greenstein G, Greenstein B, Cavallaro J, Elian N, Tarnow D. Flap advancement: practical techniques to attain tension-free primary closure. *J Periodontol.* 2009;80(1):4-15.
 119. Fontana F, Santoro F, Maiorana C, Iezzi G, Piattelli A, Simion M. Clinical and histologic evaluation of allogeneic bone matrix versus autogenous bone chips associated with titanium-reinforced e-PTFE membrane for vertical ridge augmentation: a prospective pilot study. *Int J Oral Maxillofac Implants.* 2008;23(6):1003-1012.
 120. Beitelitum I, Artzi Z, Nemcovsky CE. Clinical evaluation of particulate allogeneic with and without autogenous bone grafts and resorbable collagen membranes for bone augmentation of atrophic alveolar ridges. *Clin Oral Implants Res.* 2010;21(11):1242-1250.
 121. Mazor Z, Lorean A, Mijiritsky E, Levin L. Nasal floor elevation combined with dental implant placement. *Clin Implant Dent Relat Res.* 2012;14(5):768-771.
 122. Chiapasco M, Zaniboni M, Rimondini L. Dental implants placed in grafted maxillary sinuses: a retrospective analysis of clinical outcome according to the initial clinical situation and a proposal of defect classification. *Clin Oral Implants Res.* 2008;19(4):416-428.
 123. Machado VC, Chrcanovic BR, Felipe MB, Manhaes Junior LR, de Carvalho PS. Assessment of accessory canals of the canalis sinuosus: a study of 1000 cone beam computed tomography examinations. *Int J Oral Maxillofac Surg.* 2016;45(12):1586-1591.
 124. Kablan F. Superiorization of the inferior alveolar nerve and roofing for extreme atrophic posterior mandibular ridges with dental implants. *Ann Maxillofac Surg.* 2020;10(1):142-148.
 125. Hu KS, Kwak HH, Song WC, et al. Branching patterns of the infraorbital nerve and topography within the infraorbital space. *J Craniofac Surg.* 2006;17(6):1111-1115.
 126. Kim MK, Han W, Kim SG. The use of the buccal fat pad flap for oral reconstruction. *Maxillofac Plast Reconstr Surg.* 2017;39(1):5.
 127. Tinti C, Parma-Benfenati S. Vertical ridge augmentation: surgical protocol and retrospective evaluation of 48 consecutively inserted implants. *Int J Periodontics Restorative Dent.* 1998;18(5):434-443.
 128. Ronda M, Stacchi C. Management of a coronally advanced lingual flap in regenerative osseous surgery: a case series introducing a novel technique. *Int J Periodontics Restorative Dent.* 2011;31(5):505-513.
 129. Sittitavornwong S, Babston M, Denson D, Zehren S, Friend J. Clinical anatomy of the lingual nerve: a review. *J Oral Maxillofac Surg.* 2017;75(5):926 e921-926 e929.
 130. Pistilli R, Checchi V, Sammartino G, Simion M, Felice P. Safe new approach to the lingual flap Management in Mandibular Augmentation Procedures: the Digitoclastic technique. *Implant Dent.* 2017;26(5):790-795.
 131. Urban I, Traxler H, Romero-Bustillos M, et al. Effectiveness of two different lingual flap advancing techniques for vertical bone augmentation in the posterior mandible: a comparative, Split-mouth cadaver study. *Int J Periodontics Restorative Dent.* 2018;38(1):35-40.
 132. Seymour RA, Meechan JG, Blair GS. An investigation into post-operative pain after third molar surgery under local analgesia. *Br J Oral Maxillofac Surg.* 1985;23(6):410-418.
 133. Meechan JG, Seymour RA. The use of third molar surgery in clinical pharmacology. *Br J Oral Maxillofac Surg.* 1993;31(6):360-365.
 134. Deal DN, Tipton J, Rosencrance E, Curl WW, Smith TL. Ice reduces edema. A study of microvascular permeability in rats. *J Bone Joint Surg Am.* 2002;84(9):1573-1578.
 135. Sawin PD, Dickman CA, Crawford NR, Melton MS, Bichard WD, Sonntag VK. The effects of dexamethasone on bone fusion in an experimental model of posterolateral lumbar spinal arthrodesis. *J Neurosurg.* 2001;94(1 Suppl):76-81.
 136. Pountos I, Georgouli T, Blokhuis TJ, Pape HC, Giannoudis PV. Pharmacological agents and impairment of fracture healing: what is the evidence? *Injury.* 2008;39(4):384-394.
 137. Clavero J, Lundgren S. Ramus or chin grafts for maxillary sinus inlay and local onlay augmentation: comparison of donor site morbidity and complications. *Clin Implant Dent Relat Res.* 2003;5(3):154-160.
 138. Stacchi C, Lombardi T, Cusimano P, et al. Bone scrapers versus piezoelectric surgery in the lateral antrotomy for sinus floor elevation. *J Craniofac Surg.* 2017;28(5):1191-1196.

139. Miron RJ, Hedbom E, Saulacic N, et al. Osteogenic potential of autogenous bone grafts harvested with four different surgical techniques. *J Dent Res*. 2011;90(12):1428-1433.
140. Hong JY, Shin EY, Herr Y, Chung JH, Lim HC, Shin SI. Implant survival and risk factor analysis in regenerated bone: results from a 5-year retrospective study. *J Periodontal Implant Sci*. 2020;50(6):379-391.
141. Qin Y, Liu Y, Jiang Y, et al. Cigarette smoke exposure inhibits osteoclast apoptosis via the mtROS pathway. *J Dent Res*. 2021;100(12):1378-1386.
142. Urban IA, Saleh MHA, Ravida A, Forster A, Wang HL, Barath Z. Vertical bone augmentation utilizing a titanium-reinforced PTFE mesh: a multi-variate analysis of influencing factors. *Clin Oral Implants Res*. 2021;32(7):828-839.
143. Urban IA, Monje A, Lozada J, Wang HL. Principles for vertical ridge augmentation in the atrophic posterior mandible: a technical review. *Int J Periodontics Restorative Dent*. 2017;37(5):639-645.
144. Burkhardt R, Lang NP. Role of flap tension in primary wound closure of mucoperiosteal flaps: a prospective cohort study. *Clin Oral Implants Res*. 2010;21(1):50-54.
145. Urban IA, Monje A, Nevins M, Nevins ML, Lozada JL, Wang HL. Surgical management of significant maxillary anterior vertical ridge defects. *Int J Periodontics Restorative Dent*. 2016;36(3):329-337.
146. Urban IA, Monje A, Wang HL. Vertical ridge augmentation and soft tissue reconstruction of the anterior atrophic maxillae: a case series. *Int J Periodontics Restorative Dent*. 2015;35(5):613-623.
147. Iezzi G, Perrotti V, Felice P, Barausse C, Piattelli A, Del Fabbro M. Are <7-mm long implants in native bone as effective as longer implants in augmented bone for the rehabilitation of posterior atrophic jaws? A systematic review and meta-analysis. *Clin Implant Dent Relat Res*. 2020;22(5):552-566.
148. Simion M, Jovanovic SA, Tinti C, Benfenati SP. Long-term evaluation of osseointegrated implants inserted at the time or after vertical ridge augmentation. A retrospective study on 123 implants with 1-5 year follow-up. *Clin Oral Implants Res*. 2001;12(1):35-45.
149. Urban IA, Jovanovic SA, Lozada JL. Vertical ridge augmentation using guided bone regeneration (GBR) in three clinical scenarios prior to implant placement: a retrospective study of 35 patients 12 to 72 months after loading. *Int J Oral Maxillofac Implants*. 2009;24(3):502-510.
150. Chiapasco M, Casentini P, Zaniboni M. Implants in reconstructed bone: a comparative study on the outcome of Straumann(R) tissue level and bone level implants placed in vertically deficient alveolar ridges treated by means of autogenous onlay bone grafts. *Clin Implant Dent Relat Res*. 2014;16(1):32-50.
151. Serrano B, Sanz-Sanchez I, Serrano K, Montero E, Sanz M. One-year outcomes of dental implants with a hybrid surface macro-design placed in patients with history of periodontitis: a randomized clinical trial. *J Clin Periodontol*. 2022;49(2):90-100.
152. Sicilia A, Gallego L, Sicilia P, Mallo C, Cuesta S, Sanz M. Crestal bone loss associated with different implant surfaces in the posterior mandible in patients with a history of periodontitis. A retrospective study. *Clin Oral Implants Res*. 2021;32(1):88-99.
153. French D, Cochran DL, Ofec R. Retrospective cohort study of 4,591 Straumann implants placed in 2,060 patients in private practice with up to 10-year follow-up: the relationship between crestal bone level and soft tissue condition. *Int J Oral Maxillofac Implants*. 2016;31(6):e168-e178.
154. Urban IA, Ravida A, Saleh MHA, et al. Long-term crestal bone changes in implants placed in augmented sinuses with minimal or moderate remaining alveolar bone: a 10-year retrospective case-series study. *Clin Oral Implants Res*. 2021;32(1):60-74.
155. Blanco J, Pico A, Caneiro L, Novoa L, Batalla P, Martin-Lancharro P. Effect of abutment height on interproximal implant bone level in the early healing: a randomized clinical trial. *Clin Oral Implants Res*. 2018;29(1):108-117.
156. Urban IA, Lozada JL, Nagy K, Sanz M. Treatment of severe mucogingival defects with a combination of strip gingival grafts and a xenogeneic collagen matrix: a prospective case series study. *Int J Periodontics Restorative Dent*. 2015;35(3):345-353.
157. Thoma DS, Naenni N, Figuero E, et al. Effects of soft tissue augmentation procedures on peri-implant health or disease: a systematic review and meta-analysis. *Clin Oral Implants Res*. 2018;29(Suppl 15):32-49.
158. Rocuzzo M, Savoini M, Dalmaso P, Ramieri G. Long-term outcomes of implants placed after vertical alveolar ridge augmentation in partially edentulous patients: a 10-year prospective clinical study. *Clin Oral Implants Res*. 2017;28(10):1204-1210.
159. Rocuzzo M, Layton DM, Rocuzzo A, Heitz-Mayfield LJ. Clinical outcomes of peri-implantitis treatment and supportive care: a systematic review. *Clin Oral Implants Res*. 2018;29(Suppl 16):331-350.
160. Mombelli A. Maintenance therapy for teeth and implants. *Periodontol 2000*. 2019;79(1):190-199.

How to cite this article: Urban I, Montero E, Sanz-Sánchez I, et al. Minimal invasiveness in vertical ridge augmentation. *Periodontol 2000*. 2023;91:126-144. doi:[10.1111/prd.12479](https://doi.org/10.1111/prd.12479)